

Vertical Humeral Osteotomy for Revision of Well-Fixed Humeral Components: Case Report and Operative Technique

Geoffrey S. Van Thiel, MD, MBA, Dana Piasecki, MD, and Gregory Nicholson, MD

Abstract

The increase in the number of shoulder arthroplasties has also created a paradoxical increase in the number of revision procedures. These revision surgeries can be complicated by well-fixed humeral components that require removal.

In this article, we report a representative revision arthroplasty that involved a novel technique, vertical humeral osteotomy, which allowed for safe and effective humeral stem extraction with no need for distal windows, no proximal bone loss, and no need for a long-stemmed prosthesis.

Shoulder arthroplasty has undergone rapid advances in recent years, with more options available to the practicing orthopedist. From hemiarthroplasty to either conventional or reverse total shoulder replacement, consistently good to excellent results have been reported for the treatment of proximal humerus fracture, end-stage degenerative arthritis, and rotator cuff arthropathy.¹⁻¹⁷ However, as indications expand and more shoulder arthroplasties are performed, an increase in the number of failed reconstructions and required revisions is expected.^{18,19}

The extent to which a component must be removed during revision shoulder arthroplasty depends on the mode of failure. Failures can result from glenoid erosion, glenoid component loosening, instability, infection, component malpositioning, and, seldom, humeral component loosening.¹⁸⁻²⁸ Given that the humeral component represents an uncommon mechanism for failure, revision can become particularly challenging when a well-fixed prosthesis must be removed. Extensive bone

ingrowth or a large, intact cement mantle can make humeral stem extraction precarious. The humerus differs from the femur in that the cortical bone is much thinner, creation of a safe window or L-shaped osteotomy is more difficult, and loss of tuberosities can lead to severe dysfunction. Without a safe and reliable technique for stem removal, the proximal humerus may be unnecessarily fractured or denuded of bone stock.

“The technique described in this case report will significantly lower the iatrogenic fracture rate.”

This was demonstrated by Wall and colleagues²⁹ with a 24.1% iatrogenic fracture rate in revision procedures.

Sperling and Cofield³⁰ described an anterior or medial cortical windowing technique for facilitating humeral stem removal. However, they reported a 20% rate of intraoperative fracture associated with this procedure and noted that, with refinement, further techniques

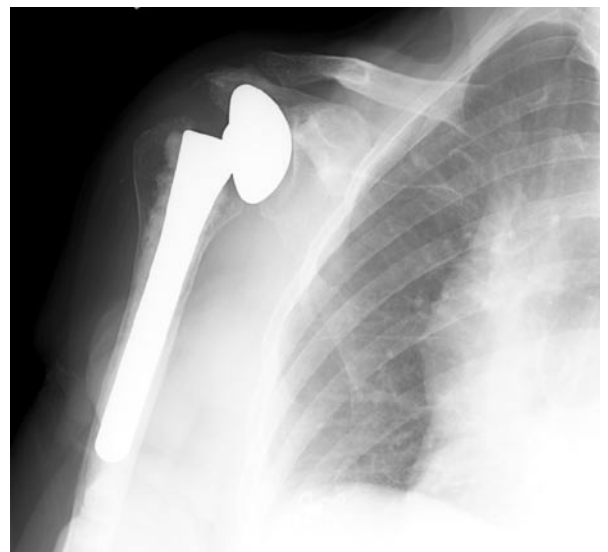


Figure 1. Preoperative radiograph shows well-fixed, cemented bipolar humeral prosthesis with medial and superior erosion.

Dr. Van Thiel is Resident, and Dr. Piasecki is Sports Medicine Fellow, Department of Orthopaedic Surgery, Rush University Medical Center, Chicago, Illinois.

Dr. Nicholson is with Division of Shoulder and Elbow, Midwest Orthopaedics at Rush, and is Associate Professor of Orthopaedic Surgery, Department of Orthopaedic Surgery, Rush University Medical Center, Chicago, Illinois.

Address correspondence to: Gregory Nicholson, MD, Midwest Orthopaedics at Rush, Rush University Medical Center, 1725 W Harrison St, Suite 1063, Chicago, IL 60612 (tel, 312-432-2300; fax, 825-642-0123; e-mail, orthonick@comcast.net).

Am J Orthop. 2009;38(2):XX-XX. Copyright, Quadrant HealthCom Inc. 2009. All rights reserved.

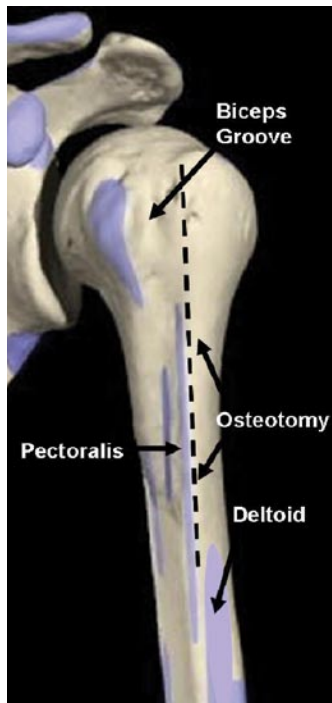


Figure 2. Osteotomy site.
© Copyright and courtesy of Primal Pictures Ltd.

could be developed to lower the fracture rate significantly. Carroll and colleagues¹⁹ as well as Petersen and Hawkins³¹ alluded to an osteotomy procedure for extraction of a humeral stem, but neither group described the technique in the literature.

In this article, we report a representative revision arthroplasty that involved a novel technique, vertical humeral osteotomy, which allowed for safe and effective humeral stem extraction with no need for distal windows, no proximal bone loss, and no need for a long-stemmed prosthesis.

CASE REPORT

At our clinic, a healthy woman in her early 80s presented with complaints of right shoulder pain and an inability to actively elevate the right arm. Four years earlier, she had undergone a bipolar hemiarthroplasty for rotator cuff tear arthropathy. She recalled that, though initially she had enjoyed modest pain relief after that surgery, she later had persistent difficulty elevating the arm. Between then and now, she had noted progressive worsening of the pain and steady deterioration in function.

The patient had a well-healed deltopectoral incision and a neurovascularly intact upper limb. Active motion was limited to 45° of elevation secondary to pain. Passive motion to 90° was possible but with significant discomfort. External rotation strength was well preserved, but the patient maintained only 3/5 forward elevation power with a subcutaneously palpable humeral prosthesis in the anterosuperior aspect of the shoulder during active flexion. The deltoid was both intact at its acromial insertion and highly functional. A complete infectious workup was negative. Radiographs showed a well-fixed cemented hemiarthroplasty with the bipolar shell tipped in varus beneath the acromion with chronic erosion apparent. Superior and medial glenoid erosion to the base of the coracoid process had also occurred (Figure 1).

Having already failed an extensive trial of conservative management, including physical therapy and steroid injections, the patient elected to undergo revision of the bipolar hemiarthroplasty to a reverse shoulder arthroplasty.

We have obtained the patient's informed, written consent to publish her case report.

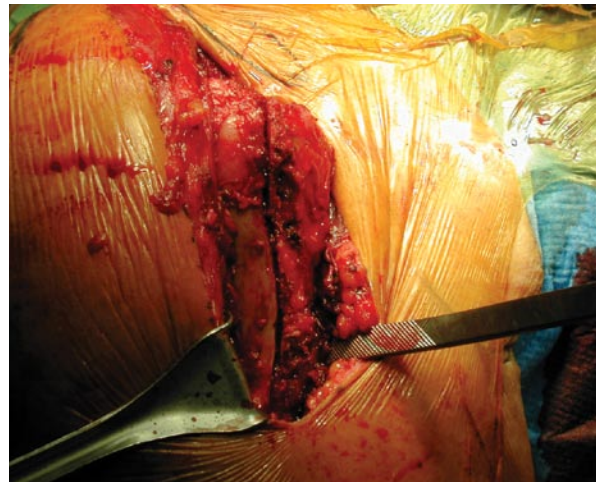


Figure 3. Vertical osteotomy before fixation (right shoulder).

TECHNIQUE

The procedure was performed with the patient under scalene regional and general anesthesia and in the beach-chair position. The previous extended deltopectoral incision was used in developing the deltopectoral interval. The humeral component was found herniating into this muscular plane during the exposure. Dense scar tissue was released from the undersurface of the deltoid and proximal humerus. The subscapularis and the superior rotator cuff were completely absent. Enhancing the humeral exposure involved releasing abundant scar tissue and remnant glenohumeral capsule from the anterior, inferior, and posterior glenoid rim. The axillary nerve was palpated and protected during this step. After this release, the proximal humerus was easily delivered into the open surgical wound with flexion and external rotation of the arm. The humeral component was well-fixed.

Our technique for removing a well-fixed humeral component, either cemented or uncemented, is to perform a vertical humeral osteotomy. This allows the surgeon to “debond” the humeral stem from the cement mantle without having to go distal to the stem tip. A small osteotome is first used around the top of the prosthesis to interrupt the interface between the implant and the tuberosity bone. Cautery is then used to expose the humerus vertically beginning just lateral to the biceps groove and extending distally between the anterior deltoid and lateral pectoralis insertions. This extends approximately 10 cm distally on the humerus (Figures 2, 3). A MicroAire oscillating saw (Model series 1000; MicroAire Surgical Instruments, Charlottesville, VA) is used to create a linear unicortical osteotomy along this vertical line, perforating both the cortex and the underlying cement mantle down to the implant. This type of saw has a small blade that is easily controllable and makes a thin cut into the bone. The osteotomy is extended distally to just below the deltoid insertion but not below the tip of the implant. Next, a series of osteotomes is used to gently “flex” open the humeral shaft at the osteotomy, with care taken to avoid fracturing the opposite cortex. The

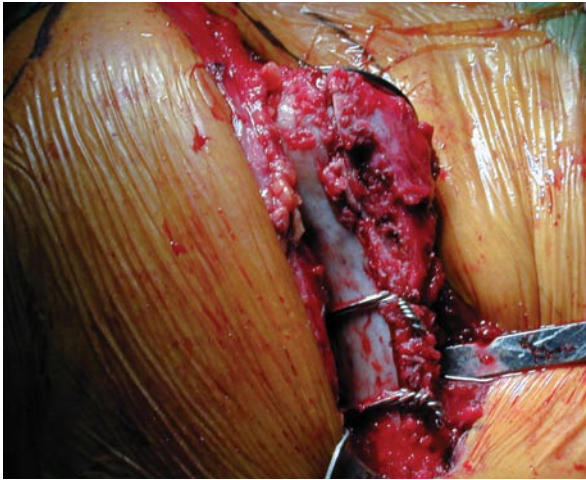


Figure 4. Vertical osteotomy stabilized with cerclage wires.

osteotomes are placed vertically within the osteotomy (perpendicular to the shaft) and gently twisted to open the humeral envelope. Gently repeating this “open book-ing” of the unicortical osteotomy several times creates a visible gap between the cement mantle and the prosthesis. There is no need to create an L-shaped cortical flap or window. Once this gap is visualized, a footed impactor is placed on the medial neck of the proximal aspect of the humeral implant. A mallet is used on the footed impactor to extract the humeral stem. Once the implant starts to move, care is taken to ensure that the tuberosity bone is not fixed to the implant. We have found the slap hammers for each specific implant design to be less reliable than this technique, and we seldom use them.

In our patient’s case, after implant removal, a portion of the remaining cement mantle was seen loosened from the surrounding cortex. Additional gentle open book-ing of the cortex facilitated removal of this mantle with osteotomes and a rongeur to a stable remnant mantle spanning roughly 50% of the prior stem length. If the reason for revision is not infection, then the entire cement mantle can be left in place, and a new implant can be cemented within it. Throughout the extraction process, the humeral shaft remained intact without propagation of the osteotomy.

Two looped 18-gauge Luque wires were then passed circumferentially around the humeral shaft (using a wire passer) and spaced evenly across the proximal-distal expanse of the osteotomy (Figure 4). A cable twister was used to lightly tighten each cerclage construct while an assistant digitally palpated the inner surface of the osteotomy to maintain an anatomical diaphyseal reduction. A metaphyseal reamer was then used to prepare the canal with the majority of the cement mantle left in place. A standard-length canal-and-mantle-filling trial stem was then inserted to protect the humeral shaft during glenoid preparation and component insertion.

Once the glenoid baseplate and glenosphere were implanted, a final test of function was completed with the trial stem and a trial humeral cup. Stability and

range of motion were deemed adequate. A size-10 stem was opened on the back table. In this specific case, the stem was longer than the position of the distal cement and plug. Instead of removing the well-osteointegrated distal cement, the surgeon shortened the stem. The tip of the prosthesis was removed with a diamond-tipped burr. Once the canal was irrigated and dried, cement was inserted in a standard semipressurized fashion using a large injection syringe and finger packing. The prepared humeral implant was then hand-inserted into the center of the cement mantle. Excess cement was removed from the osteotomy site with a freer.

Anatomical retroversion was maintained, cerclage cables were fully tightened, and the cement was allowed to harden. A very small amount of excess cement extruding from the osteotomy site was removed with a curette. Final trialing was then performed, and the corresponding humeral cup was seated on the humeral stem. The final construct was tested once more. Excellent stability and deltoid tension were noted, with no abutment to 35° of external rotation and 50° of internal rotation. Throughout vigorous passive manipulation, the vertical osteotomy remained exceptionally stable. The incision was then closed in standard fashion.

No special postoperative weight-bearing restrictions were imposed. The patient was allowed to lift only the weight of the arm for the first 6 weeks after surgery. On initial 1- and 6-week follow-up visits, she noted exceptional relief of pain and improved function (active elevation to 150° on the operative side). Radiographs showed the implant maintained in position with no evidence of loosening or fracture (Figure 5).

DISCUSSION

The increase in the number of shoulder arthroplasties has also created a paradoxical increase in the number of revision procedures. These revision surgeries can be com-

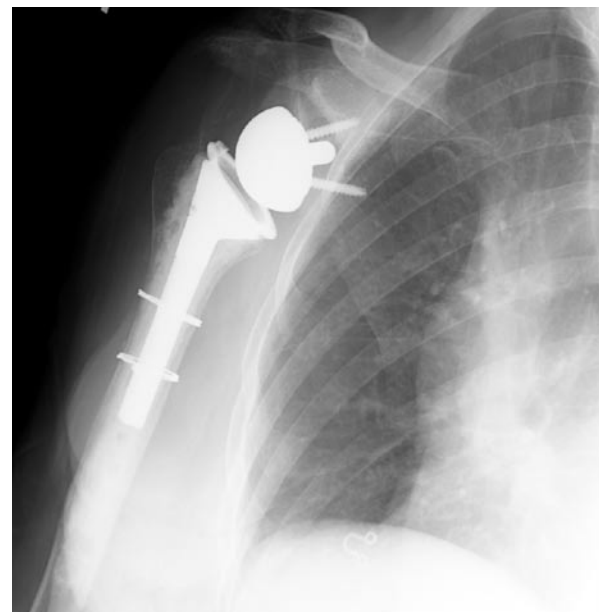

Figure 5. Six-week postoperative radiograph.

plicated by well-fixed humeral components that require removal. Traditionally, revisions have not produced satisfactory results (Carroll and colleagues¹⁹ and Sperling and Cofield³²), but new data from Wall and colleagues²⁹ and Levy and colleagues³³ showed that excellent results can be attained.^{18,34} The etiology of failure is important with respect to revision shoulder replacement. Failure occurs most often as the result of infection, instability, fracture, glenoid loosening, or progression of arthrosis. It rarely is the sequelae of humeral component loosening.³⁵ Thus, the majority of humeral components are well fixed during revision shoulder arthroplasty, and their removal presents a difficult problem that highlights the need for a safe and reliable means of stem removal.

In the revision total hip replacement literature, use of an osteotomy for removal of a prosthesis has been well established in the form of an extended trochanteric osteotomy.³⁶⁻⁴² This tool has proved to be successful in removing cemented and uncemented femoral components during revision procedures. However, an analogous technique for revision shoulder arthroplasty has received little attention. Sperling and Cofield³⁰ described using either an anterior or medial cortical window to access the humeral component. The window was resected then replaced, secured, and supplemented with allograft in 13 of 16 patients. The intraoperative fracture rate was 20%. The technique described in this case report will significantly lower the iatrogenic fracture rate and represents a unique osteotomy procedure for revision shoulder arthroplasty.

Theoretically, the described humeral osteotomy works by releasing hoop stresses in the proximal humeral shaft and significantly loosens the stem, facilitating removal. In our representative case of a well-fixed cemented stem, the implant was very easily removed from its cement mantle after completion of the osteotomy without propagation or iatrogenic fracture elsewhere in the humerus. We have used the identical technique with press-fit and proximally coated trabecular metal stems, and the ease of removal has been similar.

As in our patient's case, the supplemental cerclage wire fixation of the osteotomy provided adequate stability to the cortex and proved not to be detrimental to short-term radiographic and clinical outcomes. We have not encountered any problems with the extended soft-tissue exposure needed for the osteotomy. The osteotomy is easily performed through a standard deltopectoral approach and preserves the pectoralis major insertion on the medial side and the deltoid insertion on the lateral side of the vertical osteotomy. Also noteworthy in this case is that the bulk of the old cement mantle was left in place. Leaving the mantle in place avoids use of long-stemmed revision implants, prevents extensive loss of bone, and prevents diaphyseal perforation, which can follow attempted removal of the distal cement plug. The proposed osteotomy approach is also expedient. The entire osteotomy and stem extraction require only 10 to 15 minutes.

CONCLUSIONS

Revision shoulder arthroplasty can result in a significant improvement in patient outcome scores.⁴³ However, it does present a technical challenge with respect to implant removal and replacement. Although new prosthetic designs offer a wide variety of replacement implants, it is still essential to remove the failed prosthesis without causing additional bone loss or iatrogenic injury. A shoulder arthroplasty is most likely to fail at the glenoid through either loosening of the component or progression of arthrosis.^{20,32,44} Therefore, the humeral component remains well fixed in most cases and can be exceedingly difficult to remove.

The proposed technique significantly facilitates removal of the humeral stem in a safe and controlled manner. Long-term follow-up studies are needed to evaluate the potential for postoperative periprosthetic fracture or humeral stem loosening with this technique, but so far we have not seen these complications in our patient population. The senior author has used this technique without complication for more than 10 years. Proximal vertical humeral unicortical osteotomy facilitates efficient humeral stem removal and does not compromise bone.

AUTHORS' DISCLOSURE STATEMENT

Dr. Van Thiel and Dr. Piasecki report no actual or potential conflict of interest in relation to this article. Dr. Nicholson notes that he is a paid consultant to Zimmer and holds patents for products manufactured by Zimmer.

REFERENCES

- Zuckerman JD, Scott AJ, Gallagher MA. Hemiarthroplasty for cuff tear arthropathy. *J Shoulder Elbow Surg.* 2000;9(3):169-172.
- Frankle M, Levy JC, Pupello D, et al. The reverse shoulder prosthesis for glenohumeral arthritis associated with severe rotator cuff deficiency. A minimum two-year follow-up study of sixty patients surgical technique. *J Bone Joint Surg Am.* 2006;88(suppl 1 pt 2):178-190.
- Arntz CT, Jackins S, Matsen FA 3rd. Prosthetic replacement of the shoulder for the treatment of defects in the rotator cuff and the surface of the glenohumeral joint. *J Bone Joint Surg Am.* 1993;75(4):485-491.
- Arntz CT, Matsen FA 3rd, Jackins S. Surgical management of complex irreparable rotator cuff deficiency. *J Arthroplasty.* 1991;6(4):363-370.
- Berth A, Pap G. Hemi- versus bipolar shoulder arthroplasty for chronic rotator cuff arthropathy [published online ahead of print July 4, 2007]. *Int Orthop.* doi:10.1007/s00264-007-0394-x.
- Bryant D, Litchfield R, Sandow M, Gartsman GM, Guyatt G, Kirkley A. A comparison of pain, strength, range of motion, and functional outcomes after hemiarthroplasty and total shoulder arthroplasty in patients with osteoarthritis of the shoulder. A systematic review and meta-analysis. *J Bone Joint Surg Am.* 2005;87(9):1947-1956.
- Diaz-Borjon E, Yamakado K, Pinilla R, Keith P, Worland RL. Shoulder replacement in end-stage rotator cuff tear arthropathy: 5- to 11-year follow-up analysis of the bi-polar shoulder prosthesis. *J Surg Orthop Adv.* 2007;16(3):123-130.
- DiGiovanni J, Marra G, Park JY, Bigliani LU. Hemiarthroplasty for glenohumeral arthritis with massive rotator cuff tears. *Orthop Clin North Am.* 1998;29(3):477-489.
- Edwards TB, Kadakia NR, Boulahia A, et al. A comparison of hemiarthroplasty and total shoulder arthroplasty in the treatment of primary glenohumeral osteoarthritis: results of a multicenter study. *J Shoulder Elbow Surg.* 2003;12(3):207-213.
- Field LD, Dines DM, Zabinski SJ, Warren RF. Hemiarthroplasty of the shoulder for rotator cuff arthropathy. *J Shoulder Elbow Surg.* 1997;6(1):18-23.
- Frankle M, Siegal S, Pupello D, Saleem A, Mighell M, Vasey M. The reverse shoulder prosthesis for glenohumeral arthritis associated with severe rotator cuff deficiency. A minimum two-year follow-up study of sixty patients. *J Bone Joint Surg Am.* 2005;87(8):1697-1705.

12. Guery J, Favard L, Sirveaux F, Oudet D, Molé D, Walch G. Reverse total shoulder arthroplasty. Survivorship analysis of eighty replacements followed for five to ten years. *J Bone Joint Surg Am.* 2006;88(8):1742-1747.
13. Laudicina L, D'Ambrosia R. Management of irreparable rotator cuff tears and glenohumeral arthritis. *Orthopedics.* 2005;28(4):382-388.
14. Lo IK, Litchfield RB, Griffin S, Faber K, Patterson SD, Kirkley A. Quality-of-life outcome following hemiarthroplasty or total shoulder arthroplasty in patients with osteoarthritis. A prospective, randomized trial. *J Bone Joint Surg Am.* 2005;87(10):2178-2185.
15. Sanchez-Sotelo J, Cofield RH, Rowland CM. Shoulder hemiarthroplasty for glenohumeral arthritis associated with severe rotator cuff deficiency. *J Bone Joint Surg Am.* 2001;83(12):1814-1822.
16. Sarris IK, Papadimitriou NG, Sotereanos DG. Bipolar hemiarthroplasty for chronic rotator cuff tear arthropathy. *J Arthroplasty.* 2003;18(2):169-173.
17. Wirth MA, Tapscott RS, Southworth C, Rockwood CA Jr. Treatment of glenohumeral arthritis with a hemiarthroplasty. Surgical technique. *J Bone Joint Surg Am.* 2007;89(suppl 2 pt 1):10-25.
18. Dines JS, Fealy S, Strauss EJ, et al. Outcomes analysis of revision total shoulder replacement. *J Bone Joint Surg Am.* 2006;88(7):1494-1500.
19. Carroll RM, Izquierdo R, Vazquez M, Blaine TA, Levine WN, Bigliani LU. Conversion of painful hemiarthroplasty to total shoulder arthroplasty: long-term results. *J Shoulder Elbow Surg.* 2004;13(6):599-603.
20. Neyton L, Sirveaux F, Roche O, Molé D, Boileau P, Walch G. Results of revision surgery for glenoid loosening: a multicentric series of 37 shoulder prostheses [in French]. *Rev Chir Orthop Reparatrice Appar Mot.* 2004;90(2):111-121.
21. Hasan SS, Leith JM, Campbell B, Kapil R, Smith KL, Matsen FA 3rd. Characteristics of unsatisfactory shoulder arthroplasties. *J Shoulder Elbow Surg.* 2002;11(5):431-441.
22. Kumar S, Sperling JW, Haidukewych GH, Cofield RH. Periprosthetic humeral fractures after shoulder arthroplasty. *J Bone Joint Surg Am.* 2004;86(4):680-689.
23. Lervick GN, Carroll RM, Levine WN. Complications after hemiarthroplasty for fractures of the proximal humerus. *Instr Course Lect.* 2003;52:3-12.
24. Moeckel BH, Altchek DW, Warren RF, Wickiewicz TL, Dines DM. Instability of the shoulder after arthroplasty. *J Bone Joint Surg Am.* 1993;75(4):492-497.
25. Noble JS, Bell RH. Failure of total shoulder arthroplasty: why does it occur? *Semin Arthroplasty.* 1995;6(4):280-288.
26. Ryckaert A, Nelen G, Stuyck J, Debeer P. Superior instability of a shoulder hemiarthroplasty with skin perforation. *Orthopedics.* 2007;30(11):968-969.
27. Sanchez-Sotelo J, Sperling JW, Rowland CM, Cofield RH. Instability after shoulder arthroplasty: results of surgical treatment. *J Bone Joint Surg Am.* 2003;85(4):622-631.
28. Sperling JW, Antuna SA, Sanchez-Sotelo J, Schleck C, Cofield RH. Shoulder arthroplasty for arthritis after instability surgery. *J Bone Joint Surg Am.* 2002;84(10):1775-1781.
29. Wall B, Nove-Josserand L, O'Connor DP, Edwards TB, Walch G. Reverse total shoulder arthroplasty: a review of results according to etiology. *J Bone Joint Surg Am.* 2007;89(7):1476-1485.
30. Sperling JW, Cofield RH. Humeral windows in revision shoulder arthroplasty. *J Shoulder Elbow Surg.* 2005;14(3):258-263.
31. Petersen SA, Hawkins RJ. Revision of failed total shoulder arthroplasty. *Orthop Clin North Am.* 1998;29(3):519-533.
32. Sperling JW, Cofield RH. Revision total shoulder arthroplasty for the treatment of glenoid arthrosis. *J Bone Joint Surg Am.* 1998;80(6):860-867.
33. Levy J, Frankle M, Mighell M, Pupello D. The use of the reverse shoulder prosthesis for the treatment of failed hemiarthroplasty for proximal humeral fracture. *J Bone Joint Surg Am.* 2007;89(2):292-300.
34. Deutsch A, Abboud JA, Kelly J, et al. Clinical results of revision shoulder arthroplasty for glenoid component loosening. *J Shoulder Elbow Surg.* 2007;16(6):706-716.
35. Wirth MA, Rockwood CA Jr. Complications of shoulder arthroplasty. *Clin Orthop.* 1994;(307):47-69.
36. Peters PC Jr, Head WC, Emerson RH Jr. An extended trochanteric osteotomy for revision total hip replacement. *J Bone Joint Surg Br.* 1993;75(1):158-159.
37. Miner TM, Momberger NG, Chong D, Papprosky WL. The extended trochanteric osteotomy in revision hip arthroplasty: a critical review of 166 cases at mean 3-year, 9-month follow-up. *J Arthroplasty.* 2001;16(8 suppl 1):188-194.
38. Chassin EP, Silverton CD, Berzins A, Rosenberg AG. Implant stability in revision total hip arthroplasty: allograft bone packing following extended proximal femoral osteotomy. *J Arthroplasty.* 1997;12(8):863-868.
39. Chen WM, McAuley JP, Engh CA Jr, Hopper RH Jr, Engh CA. Extended slide trochanteric osteotomy for revision total hip arthroplasty. *J Bone Joint Surg Am.* 2000;82(9):1215-1219.
40. Engh CA Jr, McAuley JP, Engh C Sr. Surgical approaches for revision total hip replacement surgery: the anterior trochanteric slide and the extended conventional osteotomy. *Instr Course Lect.* 1999;48:3-8.
41. Masri BA, Campbell DG, Garbuz DS, Duncan CP. Seven specialized exposures for revision hip and knee replacement. *Orthop Clin North Am.* 1998;29(2):229-240.
42. Papprosky WG, Martin EL. Cemented stem failure requires extended trochanteric osteotomy. *Orthopedics.* 2003;26(1):28, 38.
43. De Wilde L, Mombert M, Van Petegem P, Verdonk R. Revision of shoulder replacement with a reversed shoulder prosthesis (Delta III): report of five cases. *Acta Orthop Belg.* 2001;67(4):348-353.
44. Levine WN, Djurasovic M, Glasson JM, Pollock RG, Flatow EL, Bigliani LU. Hemiarthroplasty for glenohumeral osteoarthritis: results correlated to degree of glenoid wear. *J Shoulder Elbow Surg.* 1997;6(5):449-454.

This paper will be judged for the Resident Writer's Award.
