



The vertical humeral osteotomy for stem removal in revision shoulder arthroplasty: results and technique

Geoffrey S. Van Thiel, MD*, James P. Halloran, MD, Stacy Twigg, PA-C,
Anthony A. Romeo, MD, Gregory P. Nicholson, MD

Department of Orthopaedics, Division of Shoulder and Elbow, Rush University Medical Center, Chicago, IL, USA

Hypothesis: Revision shoulder arthroplasty represents a complex and difficult problem for the treating surgeon, with multiple potential complications. In the setting of a well-fixed humeral component, removal can lead to fractures and compromise the outcome of the revision. The current study describes and evaluates the results of a novel vertical humeral osteotomy (VHO) for stem extraction. We hypothesized that the VHO will enable successful stem extraction without perioperative or postoperative fractures.

Materials and methods: Twenty-seven patients were retrospectively identified who had a VHO for revision shoulder arthroplasty, with 23 patients available for final follow-up. Records and radiographs were reviewed for postoperative complications. Final follow-up was completed with the inclusion of shoulder scores.

Results: There were no perioperative or postoperative fractures on clinical examination and radiographic review at an average follow-up of 41 months. Average American Shoulder and Elbow Surgeons (ASES) score was 64.7 (contralateral ASES, 76.9), average Simple Shoulder Test was 6.3, and the visual analog score pain average was 1.3. There were no instability events.

Discussion: The glenoid is the more common site for failure in both hemiarthroplasty and total shoulder arthroplasty. This can lead to a difficult revision procedure if the ingrown or cemented humeral stem requires removal.

Conclusion: In the current study, we found the VHO was an effective tool for the removal of the humeral prosthesis with no perioperative or postoperative fractures.

Level of evidence: Level IV, Case Series, Treatment Study.

© 2011 Journal of Shoulder and Elbow Surgery Board of Trustees.

Keywords: Shoulder; arthroplasty; revision; humeral; prosthesis

Shoulder arthroplasty has experienced an exponential increase in available implants, indications, and techniques in contemporary orthopedics. Good to excellent results have been reported with both hemiarthroplasties and total shoulder replacements for the treatment of proximal

humerus fractures, end-stage degenerative arthritis, and rotator cuff arthropathy.^{1-4,10,11,13,15-17,19,22,26,36,38,45,46}

However, as the frequency of primary shoulder arthroplasty increases, the number of failures and required revisions will also grow.^{5,12}

Revision shoulder arthroplasty represents a complex and difficult problem for the treating surgeon. The extent to which component removal is necessary depends on the mode of failure. Failures can manifest due to glenoid erosion, glenoid component loosening, instability, infection, component malposition, and rarely, humeral component

The Rush University Medical Center Investigational Review Board approved this study.

*Reprint requests: Geoffrey S. Van Thiel, MD, Department of Orthopedics, 1611 W Harrison St, Ste 200, Chicago, IL 60612.

E-mail address: gsvanthiel@gmail.com (G.S. Van Thiel).

loosening.^{5,20,21,23,29-31,35,37,39} In the context of revision surgery with a well fixed humeral component that requires removal, the procedure can be extremely challenging, with significant complications. Extensive bone ingrowth and a large, intact cement mantle contribute to the difficulty with extraction of the humeral stem. However, the thin cortical bone of the humerus makes it difficult to create a safe window or L-shaped osteotomy. Resultant fracture or loss of tuberosity integrity can lead to severe postoperative dysfunction. Thus, without a safe and reliable technique for stem removal, the proximal humerus may be unnecessarily fractured or denuded of bone stock.

Sperling et al⁴⁰ has previously described an anterior or medial cortical windowing technique to facilitate humeral stem removal. However, they reported a 20% rate of intraoperative fracture associated with this procedure and noted that, with refinement, further techniques could be developed that significantly lowered this rate. Subsequently, we have developed a vertical humeral osteotomy (VHO) technique to remove both cemented and uncemented humeral components, as described previously.⁴² The technique was designed to allow component removal without significant damage to the proximal humerus and to avoid distal windows, thus allowing reimplantation without the need for a long stem implant.

The purposes of the current study were to describe the VHO technique, report the perioperative complications, and evaluate the longer-term follow-up results. We hypothesized that the VHO would enable successful stem extraction without perioperative or postoperative fractures.

Materials and methods

We retrospectively identified 27 patients (16 women, 11 men) who required a VHO for humeral stem removal in a revision arthroplasty. Of these, 23 were available for final follow-up: 2 had died of unrelated causes, and 2 could not be located. Patients were clinically evaluated at postoperative intervals of 1 week, 1, 3, and 6 months, 1 year, and then at yearly intervals. Postoperative radiographs were obtained in the true anteroposterior (AP), lateral, and axillary planes at 3 months, 6 months, 1 year, and then annually thereafter. Clinical scores were obtained and recorded at final follow-up, including the American Shoulder and Elbow Surgeons (ASES) score, Simple Shoulder Test (SST), and visual analog scale (VAS) for pain. Radiographs from each follow-up visit were reviewed for fractures or component loosening. Finally, all operative reports were analyzed for notations of fracture, complication, or loss of tuberosity integrity.

The average follow-up was 40.9 months (range, 24-98 months). The average age at revision was 69 years (range, 52-81 years). There were 14 cemented stems and 9 uncemented humeral stems. Seven arthroplasties were initially infected, but the humeral stem (5 cemented, 2 uncemented) was not loose, therefore requiring a VHO for removal.

The presenting etiology for the original arthroplasty was fracture in 10 patients, cuff tear arthropathy in 7, and osteoarthritis in 6. The subsequent revision arthroplasties included hemiarthroplasty

to reverse in 14 patients, hemiarthroplasty to total shoulder arthroplasty in 6, total shoulder arthroplasty to reverse in 1, and hemiarthroplasty to hemiarthroplasty in 2. In the 7 infections, a spacer was placed for 6 to 8 weeks, and the secondary exchange was performed by removing the spacer and implanting the new component. The VHO had been performed to remove the primary stem and was not disturbed at the secondary reimplantation.

Surgical technique

The VHO procedure is performed under scalene regional and general anesthesia in the beach chair position. The previous deltopectoral incision is used in developing the deltopectoral interval; occasionally, this will need to be extended. Dense scar tissue should be released from the undersurface of the deltoid and proximal humerus. If the subscapularis tendon is still present, it is released off the lesser tuberosity and reflected medially. To enhance humeral exposure, abundant scar tissue and remnant glenohumeral capsule are released from the anterior, inferior, and posterior glenoid rim. The axillary nerve is palpated and protected during this step. After this release, the proximal humerus is easily delivered into the open surgical wound with flexion and external rotation of the arm.

The VHO is then used to remove a well-fixed humeral component, either cemented or uncemented. This allows the surgeon to “debond” the humeral stem from the cement mantle without having to go distal to the stem tip. A small osteotome is first used around the top of the prosthesis to interrupt the interface between the implant and the tuberosity bone (Fig. 1). This is an important step to eliminate adhesion of the thin tuberosity bone to the implant or cement mantle. The prosthetic head is removed, and a 0.25-inch curved osteotome is tapped down around the proximal aspect of the humeral component circumferentially.

Cautery is used to expose the humerus vertically, beginning just lateral to the biceps groove and extending distally between the anterior deltoid and lateral pectoralis tendon insertions. This extends approximately 10 cm distally on the humerus (Figs. 2 and 3). A MicroAire oscillating saw (MicroAire Series 1000, MicroAire, Charlottesville, VA) is used to create a linear unicortical osteotomy along this vertical line, perforating both the cortex and underlying cement mantle down to the implant. This type of saw has a small blade that is easily controllable and makes a thin cut into the bone. The osteotomy is extended distally to just below the deltoid insertion but not below the tip of the implant.

Next, a series of osteotomes are used to gently “flex” open the humeral shaft at the osteotomy. Care is taken to avoid fracturing the opposite cortex (Fig. 4). The osteotomes are placed vertically within the osteotomy (perpendicular to the shaft) and gently twisted to open the humeral envelope. Gently repeating this “open booking” of the unicortical osteotomy on several occasions creates a visible gap between the cement mantle and prosthesis. There is no need to create an L-shaped cortical flap or window.

Once this gap is visualized, a footed impactor is placed on the medial neck of the proximal aspect of the humeral implant (Fig. 5). A mallet is used on the footed impactor to extract the humeral stem. Once the implant starts to move, care is taken to make sure the tuberosity bone is not fixed to the implant. We have found that implant-specific slap-hammers are less reliable than this technique.

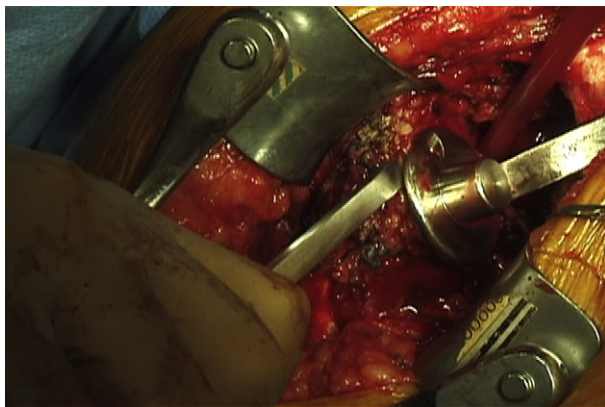


Figure 1 Osteotomes are used on the proximal collar to “debond” the implant and facilitate removal without violating the tuberosities.

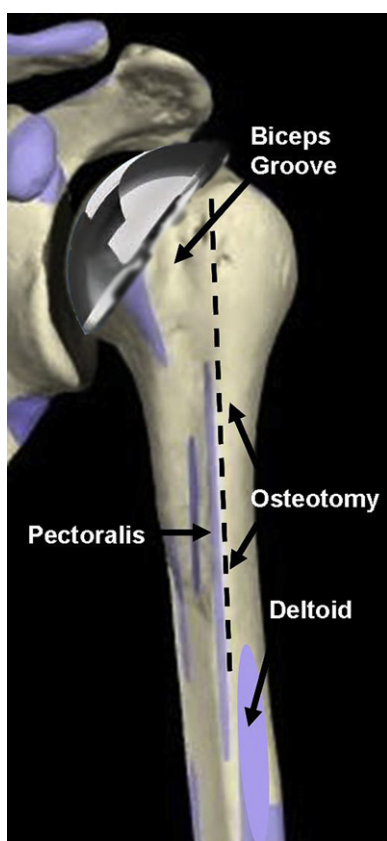


Figure 2 The osteotomy is located lateral to the biceps groove, between the pectoralis and deltoid insertions.

After the implant is removed, a portion of the remaining cement mantle may be loosened from the surrounding cortex. Additional gentle “open booking” of the cortex facilitates removal of this mantle with osteotomes and a rongeur to a stable remnant mantle. If the need for revision is not an infectious process, then the entire cement mantle does not need to be removed. A new implant can be cemented into the old cement mantle. In the setting of an infection, all foreign material is

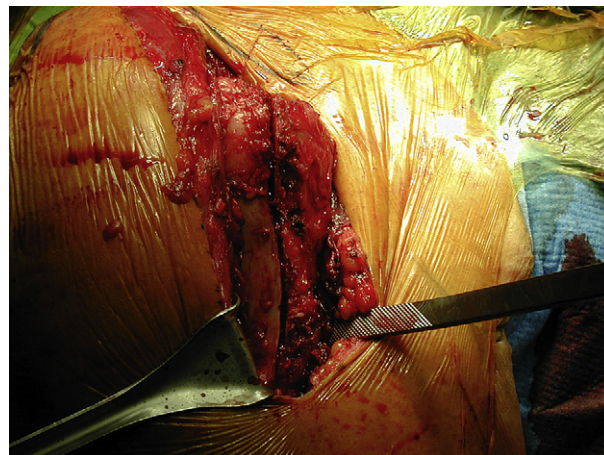


Figure 3 The vertical osteotomy is shown before fixation.

removed, including the entire cement mantle and the distal plug. This can be done without extending the osteotomy through the use of an ultrasonic cement remover (Ultra-Drive, Biomet, Warsaw, IN) and with small bone hooks for extraction of the plug. Throughout the extraction process, the humeral shaft remains intact, without propagation of the osteotomy.

Two looped 18-gauge Luque wires are then passed circumferentially around the humeral shaft using a wire passer and spaced evenly across the proximal-distal expanse of the osteotomy (Fig. 6). A cable twister is used to lightly tighten each cerclage construct, with an assistant digitally palpating the inner surface of the osteotomy to maintain an anatomic diaphyseal reduction. A metaphyseal reamer is then used to prepare the canal by hand, with most of the cement mantle left in place. A standard length, canal, and mantle filling trial stem can then be inserted to protect the humeral shaft during glenoid preparation and component insertion (Fig. 7).

Results

Twenty-three patients were available for follow-up at a mean of 41 months. All revision stems were cemented: 9 were cemented into existing cement mantles, and the other 14 were cemented into the diaphyseal tube. Seven of these were a primary exchange of an uncemented stem to a revision cemented standard length stem. The other 7 were secondary re-implantations after spacer removal for infection treated by implant removal by VHO. All revision stems were standard length, with no long stem components being necessary.

No distal window or L-shaped diaphyseal osteotomies were required to remove the primary stems. There were no intraoperative diaphyseal or metaphyseal fractures. Follow-up radiographs revealed no implant-cement lucencies or loosening at an average of 41 months and no extruded cement was seen in the diaphyseal region. No periprosthetic fractures have occurred. There were no cerclage wire complications. No implant specific extractor devices or slap hammers were used with the VHO technique.

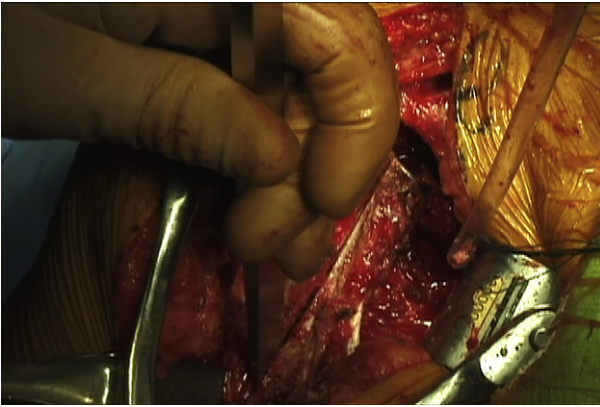


Figure 4 Osteotomies are sequentially used to flex open the humerus.

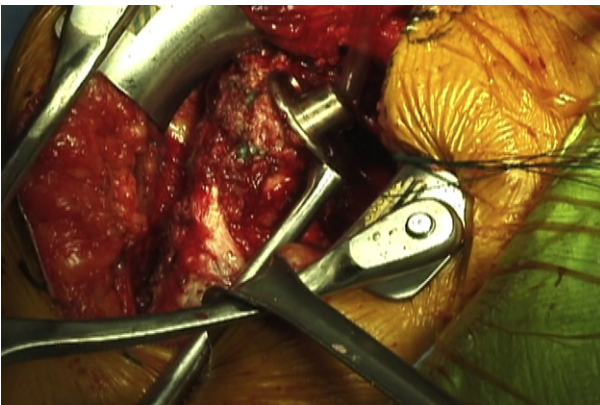


Figure 5 A footed impactor is placed on the proximal implant to remove the prosthesis.

Shoulder function outcome scores were variable. At an average follow-up of 41 months, average ASES score was 64.7 (contralateral ASES, 76.9), average SST was 6.3, and the VAS pain average was 1.3. There were no instability events. All patients stated they would undergo the procedure again and were pleased with the result.

Discussion

The continued growth and refinement of shoulder arthroplasty will also result in an increase in revision surgery. Multiple authors have shown that excellent results can be attained; however, the techniques required can be complex.^{9,12,25,43} The etiology of failure is an important component when planning the revision procedure. The glenoid is the most common site for malfunction through loosening of the component or progression of arthrosis on the native articular surface. Less commonly, the humerus can be involved with component malposition, instability, infection, fracture, and, atypically, humeral component loosening.⁴⁴ Thus, a well-fixed humeral prosthesis creates a difficult

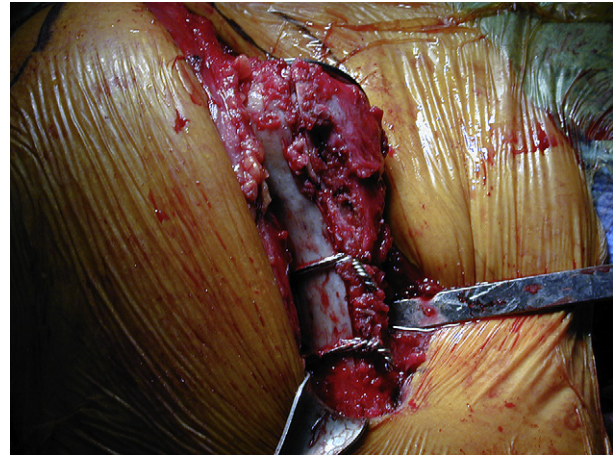


Figure 6 The vertical osteotomy has been stabilized with cerclage wires.

problem and emphasizes the importance of a safe and reliable means of stem removal. This fact was highlighted by Wall and Walch⁴³ in their review of reverse shoulder replacements, “during thirteen (24.1%) of the fifty-four revision procedures, a humeral fracture occurred during removal of the primary prosthesis or cement mantle.”

The concept of an osteotomy for removal of a prosthesis has been well established in the revision total hip literature in the form of an extended trochanteric osteotomy.^{6,7,14,27,28,32,33} This has proven to be a successful tool in removing cemented and uncemented femoral components during revision procedures. However, an analogous technique for revision shoulder arthroplasty has received little attention:

- Carroll et al⁵ and Peterson et al³⁴ alluded to an osteotomy procedure for extraction of a humeral stem, but neither described the technique.
- Sperling et al⁴⁰ reported using an anterior or medial cortical window to access the humeral component. The window was resected then replaced, secured, and supplemented with allograft in 13 of 16 patients. Of note, they reported a 20% intraoperative fracture rate.
- Gohlke and Rolf¹⁸ described a vascularized humeral window technique based on the pectoralis insertion. They reported no loosening at final follow-up in 34 patients, with 8 complications including dislocation, infection, and a fracture in the postoperative period. However, this technique requires 2 osteotomies with a technically difficult medial osteotomy under the insertion of the pectoralis insertion. This potentially creates 2 issues: complications with the replacement and healing of the “window” piece as well as a difficulty in successful reproduction of the medial osteotomy.

Overall, the shortcomings of the reported techniques led to the development and refinement of the VHO technique.

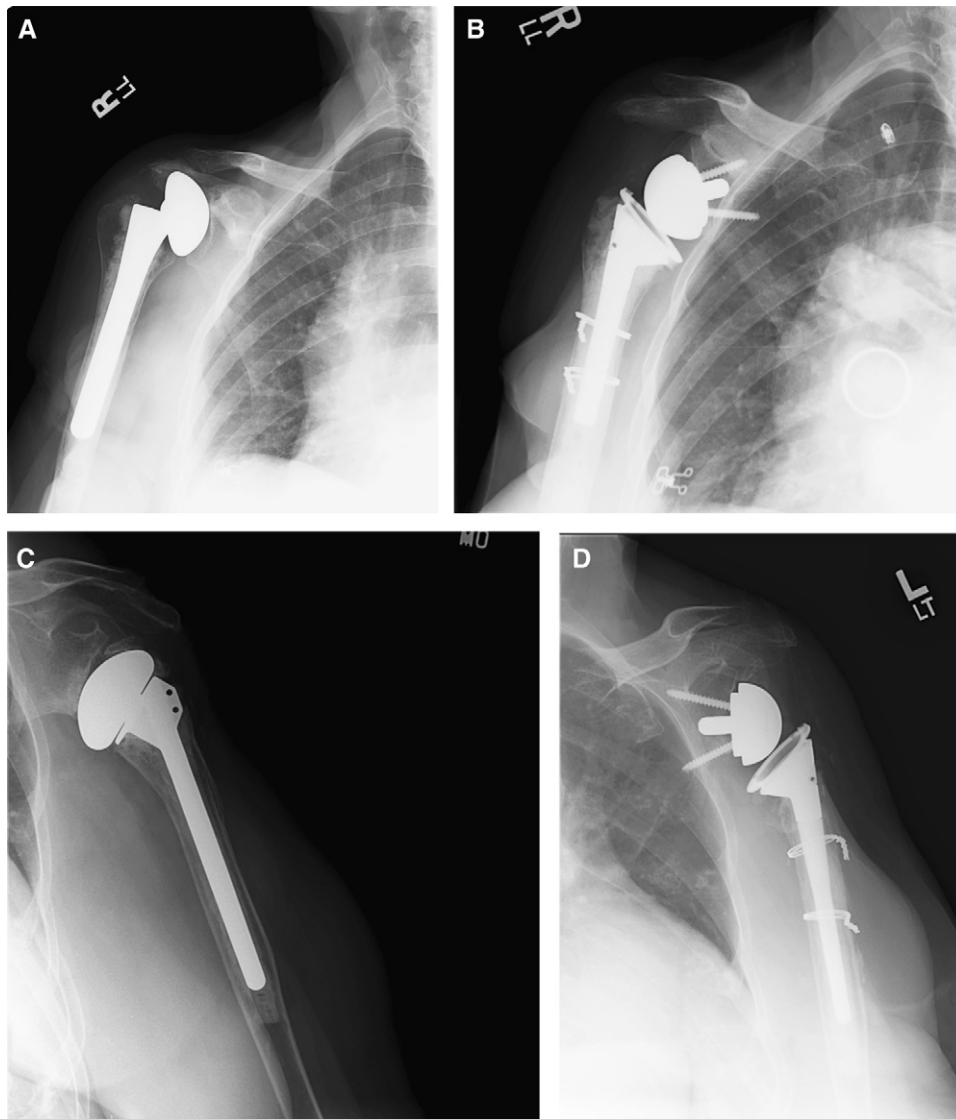


Figure 7 (A) A preoperative x-ray image. (B) A postoperative x-ray image shows placement of cerclage wires. (C) A preoperative x-ray. (D) A postoperative x-ray image shows placement of cerclage wires.

In the current study, the VHO represents a unique osteotomy procedure for revision shoulder arthroplasty that has demonstrated no iatrogenic fractures in this case series. Twenty-three patients had good outcomes at an average of 41 months, with no perioperative or postoperative fractures. The wide range of outcomes scores is the result of a variety of failure etiologies in patients with a spectrum of functional demands.

However, there are significant limitations to the current study. The functional demands of the patients may not be representative of every patient population. A patient with high functional demands may have a higher propensity for fracture. Also, these patients were identified retrospectively and complications were not collected prospectively. Although the operative reports and clinic notes were thorough, the potential for undocumented complications does exist. However, the senior author (G.N.) has used this

technique for more than 10 years, and these patients are contained within a solitary practice.

Theoretically, the described humeral osteotomy works by releasing hoop stresses in the proximal humeral shaft. This greatly loosens the stem and facilitates removal of a well-fixed component without propagation or iatrogenic fracture elsewhere in the humerus. We have used this technique with press-fit and proximally coated trabecular metal stems, as well as with cemented stems, and enjoyed a similar ease of removal. The supplemental cerclage wire fixation of the osteotomy provided adequate stability to the cortex and did not detrimentally influence the radiographic and clinical outcomes. We also have not found any problem with the extended soft-tissue exposure necessary for the osteotomy. It is easily performed through a standard deltopectoral approach and preserves the pectoralis major insertion on the medial side and the deltoid insertion on the

lateral side of the vertical osteotomy. The VHO technique leaves the distal cement plug intact, therefore avoiding the use of long-stem revision implants and the extensive bone loss or diaphyseal perforation that can follow the attempted removal. The proposed osteotomy approach is also quite expedient. The entire osteotomy and stem extraction requires only 10 to 15 minutes.

Revision shoulder arthroplasty presents a technical challenge with regard to implant removal and replacement. New prosthetic designs offer surgeons a wide variety of replacement implants; however, it is still essential to successfully remove the failed prosthesis without causing further bone loss or iatrogenic injury. Nevertheless, as recently described in the literature, revision shoulder arthroplasty can result in a significant improvement in outcome scores for the patient.⁸ When an arthroplasty fails, it is most likely at the glenoid through either loosening of the component or progression of arthrosis.^{24,30,41} The humeral component remains well-fixed in most cases. The proposed technique greatly facilitates the removal of the humeral stem in a safe and controlled manner.

Conclusion

In conclusion, although long-term follow-up studies are needed to evaluate the potential for postoperative peri-prosthetic fracture or humeral stem loosening, or both, with this technique, we have not seen these complications in our patient population. The vertical humeral unicortical osteotomy does facilitate efficient humeral stem removal, with no compromise of proximal bone, and can be recommended in revision shoulder arthroplasty cases.

Disclaimer

Dr Nicholson is a designer and consultant for Zimmer. Dr Romeo is a designer and consultant for Arthrex. The other authors, their immediate families, and any research foundations with which they are affiliated have not received any financial payments or other benefits from any commercial entity related to the subject of this article.

References

- Arntz CT, Jackins S, Matsen FA 3rd. Prosthetic replacement of the shoulder for the treatment of defects in the rotator cuff and the surface of the glenohumeral joint. *J Bone Joint Surg Am* 1993;75:485-91.
- Arntz CT, Matsen FA 3rd, Jackins S. Surgical management of complex irreparable rotator cuff deficiency. *J Arthroplasty* 1991;6:363-70.
- Berth A, Pap G. Hemi- versus bipolar shoulder arthroplasty for chronic rotator cuff arthropathy. *Int Orthop* 2007;32:735-40. doi:10.1007/s00264-007-0394-x
- Bryant D, Litchfield R, Sandow M, Gartsman GM, Guyatt G, Kirkley A. A comparison of pain, strength, range of motion, and functional outcomes after hemiarthroplasty and total shoulder arthroplasty in patients with osteoarthritis of the shoulder. A systematic review and meta-analysis. *J Bone Joint Surg Am* 2005;87:1947-56. doi:10.2106/JBJS.D.02854
- Carroll RM, Izquierdo R, Vazquez M, Blaine TA, Levine WN, Bigliani LU. Conversion of painful hemiarthroplasty to total shoulder arthroplasty: Long-term results. *J Shoulder Elbow Surg* 2004;13:599-603. doi:10.1016/S1058274604001338
- Chassin EP, Silverton CD, Berzins A, Rosenberg AG. Implant stability in revision total hip arthroplasty: allograft bone packing following extended proximal femoral osteotomy. *J Arthroplasty* 1997; 12:863-8.
- Chen WM, McAuley JP, Engh CA Jr, Hopper RH Jr, Engh CA. Extended slide trochanteric osteotomy for revision total hip arthroplasty. *J Bone Joint Surg Am* 2000;82:1215-9.
- De Wilde L, Mombert M, Van Petegem P, Verdonk R. Revision of shoulder replacement with a reversed shoulder prosthesis (Delta III): report of five cases. *Acta Orthop Belg* 2001;67:348-53.
- Deutsch A, Abboud JA, Kelly J, Mody M, Norris T, Ramsey ML, et al. Clinical results of revision shoulder arthroplasty for glenoid component loosening. *J Shoulder Elbow Surg* 2007;16:706-16. doi:10.1016/j.jse.2007.01.007
- Diaz-Borjon E, Yamakado K, Pinilla R, Keith P, Worland RL. Shoulder replacement in end-stage rotator cuff tear arthropathy: 5- to 11-year follow-up analysis of the bi-polar shoulder prosthesis. *J Surg Orthop Adv* 2007;16:123-30.
- DiGiovanni J, Marra G, Park JY, Bigliani LU. Hemiarthroplasty for glenohumeral arthritis with massive rotator cuff tears. *Orthop Clin North Am* 1998;29:477-89.
- Dines JS, Fealy S, Strauss EJ, Allen A, Craig EV, Warren RF, et al. Outcomes analysis of revision total shoulder replacement. *J Bone Joint Surg Am* 2006;88:1494-500. doi:10.2106/JBJS.D.02946
- Edwards TB, Kadakia NR, Boulahia A, Kempf JF, Boileau P, Nemoz C, et al. A comparison of hemiarthroplasty and total shoulder arthroplasty in the treatment of primary glenohumeral osteoarthritis: results of a multicenter study. *J Shoulder Elbow Surg* 2003;12:207-13. doi:10.1016/S1058-2746(02)86804-5
- Engh CA Jr, McAuley JP, Engh C Sr. Surgical approaches for revision total hip replacement surgery: the anterior trochanteric slide and the extended conventional osteotomy. *Instr Course Lect* 1999;48: 3-8.
- Field LD, Dines DM, Zabinski SJ, Warren RF. Hemiarthroplasty of the shoulder for rotator cuff arthropathy. *J Shoulder Elbow Surg* 1997;6: 18-23.
- Frankle M, Levy JC, Pupello D, Siegal S, Saleem A, Mighell M, et al. The reverse shoulder prosthesis for glenohumeral arthritis associated with severe rotator cuff deficiency. a minimum two-year follow-up study of sixty patients surgical technique. *J Bone Joint Surg Am* 2006;88(Suppl 1 Pt 2):178-90. doi:10.2106/JBJS.F.00123
- Frankle M, Siegal S, Pupello D, Saleem A, Mighell M, Vasey M. The reverse shoulder prosthesis for glenohumeral arthritis associated with severe rotator cuff deficiency. A minimum two-year follow-up study of sixty patients. *J Bone Joint Surg Am* 2005;87:1697-705. doi:10.2106/JBJS.D.02813
- Gohlke F, Rolf O. [Revision of failed fracture hemiarthroplasties to reverse total shoulder prosthesis through the transhumeral approach: method incorporating a pectoralis-major-pedicled bone window]. *Oper Orthop Traumatol* 2007;19:185-208. doi:10.1007/s00064-007-1202-x
- Guery J, Favard L, Sirveaux F, Oudet D, Mole D, Walch G. Reverse total shoulder arthroplasty. Survivorship analysis of eighty replacements followed for five to ten years. *J Bone Joint Surg Am* 2006;88: 1742-7. doi:10.2106/JBJS.E.00851
- Hasan SS, Leith JM, Campbell B, Kapil R, Smith KL, Matsen FA 3rd. Characteristics of unsatisfactory shoulder arthroplasties. *J Shoulder Elbow Surg* 2002;11:431-41. doi:10.1067/mse.2002.125806

21. Kumar S, Sperling JW, Haidukewych GH, Cofield RH. Periprosthetic humeral fractures after shoulder arthroplasty. *J Bone Joint Surg Am* 2004;86:680-9.
22. Laudicina L, D'Ambrosia R. Management of irreparable rotator cuff tears and glenohumeral arthritis. *Orthopedics* 2005;28:382-8. quiz 89-90.
23. Lervick GN, Carroll RM, Levine WN. Complications after hemiarthroplasty for fractures of the proximal humerus. *Instr Course Lect* 2003;52:3-12.
24. Levine WN, Djurasovic M, Glasson JM, Pollock RG, Flatow EL, Bigliani LU. Hemiarthroplasty for glenohumeral osteoarthritis: results correlated to degree of glenoid wear. *J Shoulder Elbow Surg* 1997;6:449-54.
25. Levy J, Frankle M, Mighell M, Pupello D. The use of the reverse shoulder prosthesis for the treatment of failed hemiarthroplasty for proximal humeral fracture. *J Bone Joint Surg Am* 2007;89:292-300. doi:10.2106/JBJS.E.01310
26. Lo IK, Litchfield RB, Griffin S, Faber K, Patterson SD, Kirkley A. Quality-of-life outcome following hemiarthroplasty or total shoulder arthroplasty in patients with osteoarthritis. A prospective, randomized trial. *J Bone Joint Surg Am* 2005;87:2178-85. doi:10.2106/JBJS.D.02198
27. Masri BA, Campbell DG, Garbuz DS, Duncan CP. Seven specialized exposures for revision hip and knee replacement. *Orthop Clin North Am* 1998;29:229-40.
28. Miner TM, Momberger NG, Chong D, Paprosky WL. The extended trochanteric osteotomy in revision hip arthroplasty: a critical review of 166 cases at mean 3-year, 9-month follow-up. *J Arthroplasty* 2001;16:188-94.
29. Moeckel BH, Altchek DW, Warren RF, Wickiewicz TL, Dines DM. Instability of the shoulder after arthroplasty. *J Bone Joint Surg Am* 1993;75:492-7.
30. Neyton L, Sirveaux F, Roche O, Mole D, Boileau P, Walch G. [Results of revision surgery for glenoid loosening: a multicentric series of 37 shoulder prosthesis]. *Rev Chir Orthop Reparatrice Appar Mot* 2004;90:111-21. doi:RCO-02-2004-90-2-0035-1040-101019-ART2
31. Noble JS, Bell RH. Failure of total shoulder arthroplasty: why does it occur? *Semin Arthroplasty* 1995;6:280-8.
32. Paprosky WG, Martin EL. Cemented stem failure requires extended trochanteric osteotomy. *Orthopedics* 2003;26(28):38.
33. Peters PC Jr, Head WC, Emerson RH Jr. An extended trochanteric osteotomy for revision total hip replacement. *J Bone Joint Surg Br* 1993;75:158-9.
34. Petersen SA, Hawkins RJ. Revision of failed total shoulder arthroplasty. *Orthop Clin North Am* 1998;29:519-33.
35. Ryckaert A, Nelen G, Stuyck J, Debeer P. Superior instability of a shoulder hemiarthroplasty with skin perforation. *Orthopedics* 2007;30:968-9.
36. Sanchez-Sotelo J, Cofield RH, Rowland CM. Shoulder hemiarthroplasty for glenohumeral arthritis associated with severe rotator cuff deficiency. *J Bone Joint Surg Am* 2001;83:1814-22.
37. Sanchez-Sotelo J, Sperling JW, Rowland CM, Cofield RH. Instability after shoulder arthroplasty: results of surgical treatment. *J Bone Joint Surg Am* 2003;85:622-31.
38. Sarris IK, Papadimitriou NG, Sotereanos DG. Bipolar hemiarthroplasty for chronic rotator cuff tear arthropathy. *J Arthroplasty* 2003;18:169-73. doi:10.1054/arth.2003.50041
39. Sperling JW, Antuna SA, Sanchez-Sotelo J, Schleck C, Cofield RH. Shoulder arthroplasty for arthritis after instability surgery. *J Bone Joint Surg Am* 2002;84:1775-81.
40. Sperling JW, Cofield RH. Humeral windows in revision shoulder arthroplasty. *J Shoulder Elbow Surg* 2005;14:258-63. doi:10.1016/j.jse.2004.09.004
41. Sperling JW, Cofield RH. Revision total shoulder arthroplasty for the treatment of glenoid arthrosis. *J Bone Joint Surg Am* 1998;80:860-7.
42. Van Thiel G, Piasecki D, Nicholson GS. Vertical humeral osteotomy for revision of well-fixed humeral components: case report and operative technique. *Am J Orthop (Belle Mead NJ)* 2009;38:67-71.
43. Wall B, Nove-Josserand L, O'Connor DP, Edwards TB, Walch G. Reverse total shoulder arthroplasty: a review of results according to etiology. *J Bone Joint Surg Am* 2007;89:1476-85. doi:10.2106/JBJS.F.00666
44. Wirth MA, Rockwood CA Jr. Complications of shoulder arthroplasty. *Clin Orthop Relat Res* 1994;47-69.
45. Wirth MA, Tapscott RS, Southworth C, Rockwood CA Jr. Treatment of glenohumeral arthritis with a hemiarthroplasty. Surgical technique. *J Bone Joint Surg Am* 2007;89(Suppl 2 Pt 1):10-25.
46. Zuckerman JD, Scott AJ, Gallagher MA. Hemiarthroplasty for cuff tear arthropathy. *J Shoulder Elbow Surg* 2000;9:169-72.