

capsulitis will suffer long-term ROM deficits that may last more than 10 years. Clarke et al. (1975) reported that 42% of patients continued to have motion loss after 6 years of follow-up. Likewise, Schaffer et al. (1992) reported that 50% of patients managed non-operatively remained symptomatic during their long-term follow-up, which occurred 2–11 years after their initial visit (mean = 7 years). Of these patients, 60% had a measurable restriction of shoulder motion. External rotation was the most chronically restricted movement, providing further evidence that the rotator interval and coracohumeral ligament are particularly affected by adhesive capsulitis. Hand et al. (2008) tracked outcomes in 269 shoulders affected by primary adhesive capsulitis who received no treatment (95); physical therapy (55); steroid injection (139); manipulation under anesthesia (MUA) (5); MUA and

arthroscopic release (5); or MUA and arthroscopic hydrodistension (20). During the long-term follow-up (mean 52.3 months) 59% of patients reported having normal or near-normal shoulders, 35% reported persistent mild/moderate symptoms, and 6% still had severe symptoms. Persistent symptoms were reported as mild in 94% of patients, with pain being the most common complaint. Only 6% of patients complained of severe pain and/or functional loss. Patients with the most severe symptoms at condition onset had the worst long-term prognosis. In general, patients with comorbid factors, particularly diabetes, hyperthyroidism, hypothyroidism, hypoadrenalism, Parkinson's disease, cardiac disease, pulmonary disease, or cerebrovascular accident, tend to have more severe and longer lasting symptoms and tend to be more recalcitrant to treatment.

REHABILITATION FOR BICEPS TENDON DISORDERS AND SLAP LESIONS

Geoffrey S. Van Thiel, MD, MBA; Sanjeev Bhatia, MD; Neil S. Ghodadra, MD; Jonathan Yong Kim, CDR; and Matthew T. Provencher, MD, CDR, MC, USN

Injuries to the proximal biceps tendon, the distal biceps tendon, and the superior labrum-biceps anterior to posterior (SLAP) tendon complex have long been recognized as a potential source of pain and disability when not properly addressed. Disorders of the biceps tendon are particularly problematic in overhead athletes, throwers, and those who do activities of lifting overhead. As such, problems with the biceps may lead to significant functional disability in both the sport and work environment. Coupled with an improved understanding of anatomy and shoulder biomechanics, advances in surgical techniques have resulted in less invasive and more effective management of biceps tendon disorders and associated SLAP lesions. It is imperative that a rehabilitation program mirror these efforts so as to optimize patient recovery both in the nonoperative and operative setting. The following section will describe the anatomy, examination, mechanism of injury, treatment, and rehabilitation for injuries to the proximal and distal biceps tendon and their associated structures.

Rehabilitation Rationale

Normal Anatomy

The biceps tendon is one of the few tendons in the body to span two joints: the glenohumeral complex and the elbow. Tension in the tendon, therefore, largely depends on the position of the elbow, wrist, and shoulder during muscle contraction. Proximally, the biceps has two heads, one of which originates from the coracoid process (short head) and the other that begins its course from the supraglenoid tubercle and superior labrum (long head). As the tendon travels distally in the glenohumeral joint it is encased in a synovial sheath and is considered to be

intraarticular but extrasynovial. It then courses obliquely through the joint and arches over the humeral head at a 30- to 45-degree angle. As the long head exits the joint, it passes under the coracohumeral ligament and through the rotator interval into the groove between the greater and lesser tuberosities (bicipital groove). In the bicipital groove it is covered by the transverse humeral ligament with contributions from the subscapularis tendon (Fig. 3-42). Distally, the long and short heads of the biceps converge at the midshaft of the humerus then insert on the anterior aspect of the radial tuberosity. In the antecubital fossa the distal tendon blends with the bicipital aponeurosis, which helps protect the cubital fossa structures and provides an even distribution of force across the elbow.

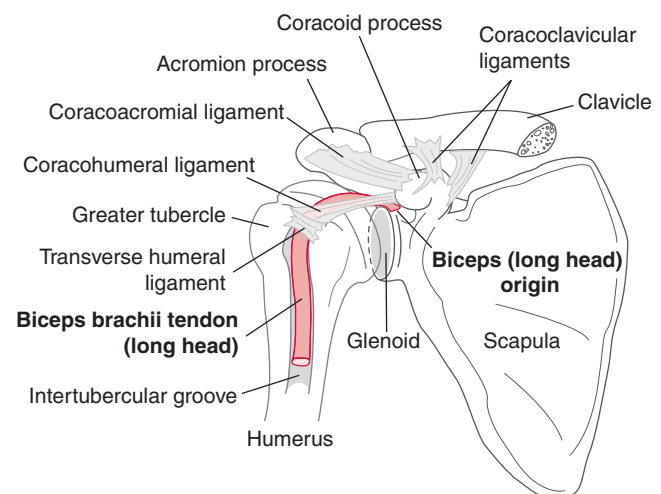


Figure 3-42 Anterior aspect of the right shoulder showing the tendon of the long head of the biceps muscle and its relationships.

Innervation of the biceps muscle is via the branches of the musculocutaneous nerve (C5). Blood supply is primarily provided by the ascending branch of the circumflex humeral artery but is augmented by the suprascapular artery proximally and the deep brachial artery distally.

Functionally, the biceps acts as a strong forearm supinator and a weak elbow flexor. However, it is more active in flexion of the supinated forearm than in flexion of the pronated forearm. Although controversial, it is also hypothesized that the long head aids in the anterosuperior stability of the humeral head by resisting torsional forces at the shoulder and preventing humeral migration; particularly evident during the vulnerable position of abduction and external rotation seen in overhead athletes. Furthermore, as demonstrated by EMG analysis, biceps contraction plays a prominent role during the cocking and deceleration phases of overhand and underhand throwing.

History and Physical Examination

Proximal Biceps and Superior Labrum

The proximal biceps tendon and the associated superior labral complex must be evaluated independently of the distal biceps, given the significant differences in mechanism of injury, evaluation, and treatment. In fact, pathologic lesions of the proximal biceps and superior labral complex can be extremely difficult to diagnose, with a multitude of potential sources for anterior shoulder pain confounding the clinical picture.

The most common presenting symptom of any biceps problem in the shoulder is pain. With isolated biceps pathology, this is usually localized to the anterior shoulder and the bicipital groove. However, the picture is less clear if the superior labrum is involved. In this case, pain can occur in the anterior or posterior aspect of the shoulder with the patient often complaining of “deep” pain. Diffuse discomfort can also occur if another condition also is present, such as rotator cuff disease, subacromial impingement, acromioclavicular joint arthrosis, or shoulder instability. Thus, an accurate history is essential and includes a description of the onset of symptoms, duration and progression of pain, history of a traumatic event, activities that worsen the pain, and previous treatments and outcomes. A SLAP tear is also associated with sensations of instability, popping, and other mechanical symptoms, especially with overhead or throwing activity. A decrease in throwing velocity or diminished overhead performance should also alert the examiner to a possible biceps or SLAP tear etiology.

A variety of reported clinical tests attempt to evaluate the proximal biceps complex, with no one test offering acceptable sensitivity and specificity. With regard to the biceps tendon, external and internal rotation can change the location of the pain with tendon movement. This helps differentiate from painful superficial structures, such as the anterior deltoid, which do not move with arm rotation. The **Yergason test** consists of resisted supination that causes anterior shoulder pain and is relatively specific for biceps pathology but tends to lack sensitivity. The **Speed test** is considered positive if pain

is localized to the proximal biceps tendon with resisted shoulder forward flexion with the forearm supinated. This pain should be decreased if the same maneuver is done with the forearm in pronation.

SLAP lesions can be more difficult to discern. A complete examination for both rotator cuff pathology and instability must be completed first. Often the patient will have positive **Neer and Hawkins shoulder impingement signs**, which can be nonspecific indicators of shoulder pathology. The **O'Brien active compression test** is often reported to be relatively specific for superior labral lesions. For this test, the shoulder is positioned in 90 degrees of flexion, slight horizontal adduction, and internal rotation. The test is considered positive when, on resisted shoulder flexion, the patient experiences deep or anterior shoulder pain that is decreased when the maneuver is repeated with the shoulder in external rotation. Overall, physical examination findings often do not reveal a specific pain generator and other techniques must be used.

Differential diagnostic injections can be helpful in evaluating biceps tendon pathology. A subacromial lidocaine injection will relieve symptomatology if rotator cuff disease is present, but it will not relieve pain with isolated biceps pathology. A shoulder intra-articular injection can decrease pain from the superior labral complex, but bicipital groove discomfort can often persist if marked inflammation or scarring prevents infiltration of the anesthetic into the groove. In these cases, direct injection into the biceps groove and sheath can be diagnostic. Evaluation of proximal biceps pathology can be complex and the patient history, physical examination, and diagnostic injections must be combined to further clarify the pain generator.

Distal Biceps

Patients with complete distal biceps tendon ruptures usually report an unexpected extension force applied to the flexed arm. Commonly, there is an associated sudden, sharp, painful tearing sensation in the antecubital region of the elbow. The intense pain subsides in a few hours and is replaced by a dull ache. Weakness in flexion is often significant in the acute rupture; however, this can dissipate with time. Weakness in supination is less pronounced and can depend on the functional demands placed on the extremity.

With an acute rupture, inspection reveals significant swelling and bruising in the antecubital fossa with associated tenderness on palpation. In fact, a defect in the biceps tendon can often be palpated if the bicipital aponeurosis has also been torn. If the tendon seems to be in continuity but is tender to palpation, a partial biceps rupture should be considered. Each of these findings should be compared to the normal side.

Radiographic Evaluation

Proximal Biceps/SLAP Lesions

Imaging of patients with proximal biceps pathology is initiated with standard plain radiographs including

a true anteroposterior (AP), axillary, and outlet view. Once other osseous pathology has been ruled out, additional imaging is ordered. An MRI scan allows for thorough evaluation of the proximal biceps and superior labral complex and other confounding shoulder pathology. Ultrasound imaging has been proposed as an inexpensive and noninvasive method for evaluating bicipital tendinopathy and ruptures, but SLAP lesions are exceedingly difficult to diagnose with ultrasound. Ultrasound may help discern if the long head of the biceps (LHB), which normally resides in the bicipital groove, is subluxed or dislocated.

The diagnosis of a complete distal biceps rupture can often be made based on the physical examination (lack of distal biceps cord, decreased forearm supination strength, bruising in the antecubital fossa); however, a partial distal biceps tear can lack the pathognomonic findings. Ultrasound can again be used, but the unreliability in diagnosis and the difficulty in evaluating partial tears make MRI the study of choice for most clinicians.

Classification

Proximal Biceps/SLAP Lesions

Injuries to the superior labral and biceps complex can be categorized into four major classifications with several minor variants (Fig. 3-43 and Table 3-8).

- Type I lesions involve a degenerative fraying of the superior labrum, with the biceps anchor intact.
- Type II injuries are detachments of the biceps anchor from the superior glenoid and are the most common type.
- Type III is a bucket handle tear of the superior labrum with an intact biceps anchor.
- Type IV lesions are similar to type III, except that the tear extends into the biceps (Fig. 3-43).

Occasionally, the proximal biceps may present with an isolated rupture and is identified with a “Popeye” deformity resulting from the distal migration of the LHB portion of the biceps muscle belly (Fig. 3-44). A variety of SLAP tears and variants are demonstrated in Figure 3-45.

Distal Biceps

Ramsey (1999) proposed a classification system for distal biceps ruptures (Table 3-9). Partial ruptures are defined by the location of the tear, whereas complete ruptures are characterized by their temporal relation to diagnosis and the integrity of the bicipital aponeurosis. Other variables include the location, chronicity, and integrity of the aponeurotic sheath. This classification helps dictate the available repair techniques.

Mechanism of Injury

Proximal Biceps Tendon and Superior Labrum

The proximal biceps tendon has multiple potential sites of injury including the biceps anchor, superior labrum, intra-articular tendon, and bicipital groove. Each location has a unique injury profile with different

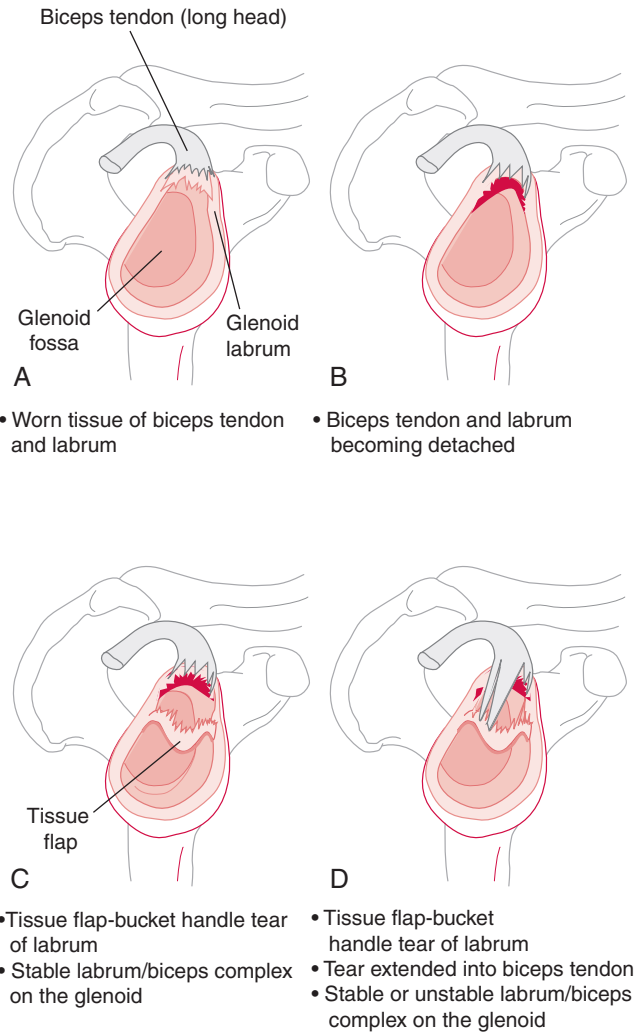


Figure 3-43 Superior labrum anterior posterior (SLAP) lesions. **A**, Type I. **B**, Type 2. **C**, Type 3. **D**, Type 4.

Table 3-8 Classification of Superior Labrum from Anterior to Posterior (SLAP) Lesions

Type	Characteristics
Type 1 SLAP	Degenerative fraying of the superior labrum but the biceps attachment to the labrum is intact. The biceps anchor is intact (see Fig. 3-43A).
Type 2 SLAP	The biceps anchor has pulled away from the glenoid attachment (see Fig. 3-43B).
Type 3 SLAP	Involve a bucket-handle tear of the superior labrum with an intact biceps anchor (see Fig. 3-43C).
Type 4 SLAP	Similar to type 3 tears but the tear also extends into the biceps tendon (see Fig. 3-43D). The torn biceps tendon and labrum are displaced into the joint.
Complex SLAP	A combination of two or more SLAP types, usually 2 and 3 or 2 and 4.

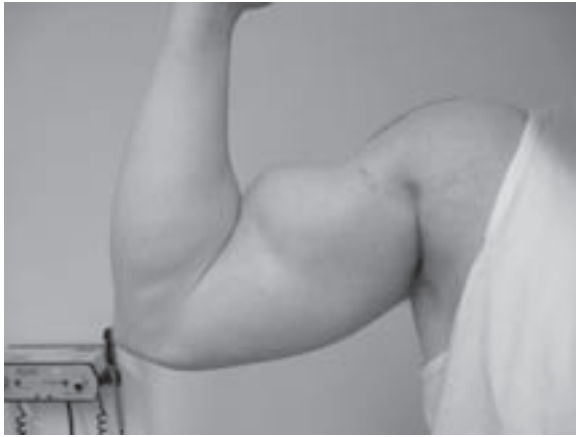

Figure 3-44 A patient who sustained a proximal biceps tendon rupture and subsequent “Popeye” deformity of the long head of the biceps tendon (LHB), which is a result of the LHB muscle belly migrating distally.

mechanisms and characteristics. These pathologic disorders can be segmented into three categories:

1. Degenerative/inflammatory
2. Instability of the tendon
3. SLAP lesions

Degeneration/inflammation: Biceps degeneration and inflammation is most likely to occur with abrasive motion as the long head of the biceps tendon runs through the bicipital groove; it is made worse with overhead and repetitive shoulder rotation activities. Although the tendon is affected by this degeneration, histologic analysis has indicated that the sheath is where actual inflammatory changes usually take place. As the degeneration and inflammation continue, the tendon becomes thickened and irregular and may become scarred to its bed through hemorrhagic adhesions. The primary cause of these degenerative changes is thought to be mechanical irritation of the tendon by osseous spurs from the anterior acromion or coracoacromial arch. Relatively recent interests have focused on repeti-

Table 3-9 Classification of Distal Biceps Injury

Partial rupture	Insertional Intrasubstance	
Complete rupture	Acute (<4 weeks)	Intact aponeurosis
	Chronic (>4 weeks)	Ruptured aponeurosis

tive motion in overhead athletes contributing to biceps pathology. Cross-body motion, internal rotation, and forward flexion have been shown to translate the humeral head anteriorly and superiorly. Thus, while the arm is in this position during the follow-through motion of throwing and hitting, anterior structures, such as the biceps, are at increased risk of impingement on the coracoacromial arch. Biceps tendon degeneration and inflammation often have an insidious onset with chronicity to the symptoms.

Instability: Biceps tendon instability can manifest from mild subluxation to complete dislocation. Laxity or discontinuity of the restraining structures and ligaments can result from either repetitive wear or trauma with subsequent biceps tendon instability. In almost all cases, subluxation or dislocation of the tendon occurs in the medial direction. According to Busconi et al. (2008), in overhead athletes as the arm is abducted and externally rotated, force vectors on the biceps tendon are directed medially. During the follow-through phase, force vectors are directed laterally. This displacement of the biceps tendon not only causes pain from biceps instability, but also results in further wear and degenerative changes resulting in anterior shoulder pain. Finally, a tear of the subscapularis can lead to biceps instability with the compromise of soft tissue restraints overlying the bicipital groove. Subscapularis tears can occur as a natural progression of chronic or acute massive rotator cuff tears and an isolated injury. The mechanism for an isolated rupture depends on the age group encountered. In younger (<40 years) athletes, there is usually a forceful hyperextension or external rotation,

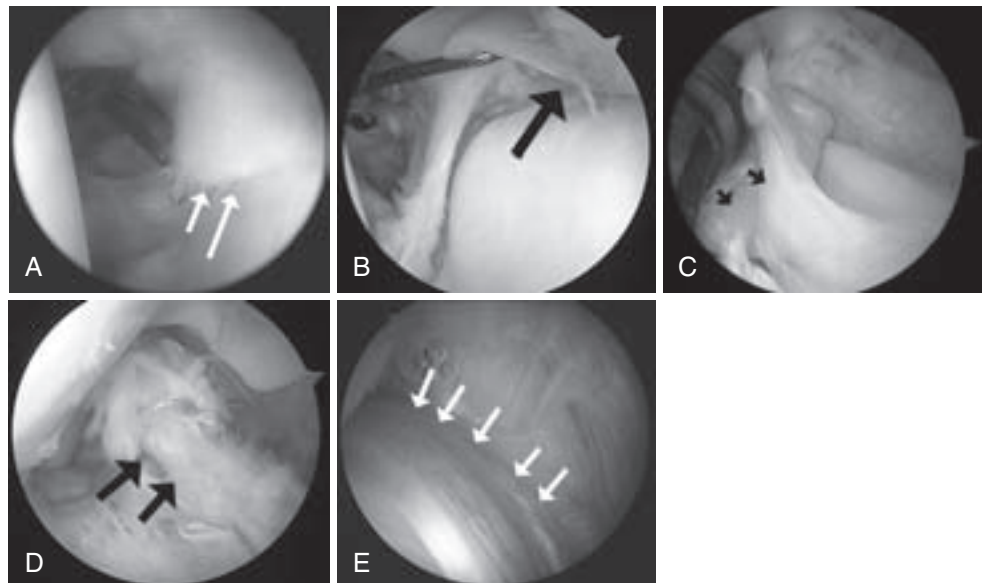


Figure 3-45 Arthroscopic images of superior labrum anterior to posterior (SLAP) lesions. **A**, SLAP I (white arrows). **B**, SLAP II (black arrow shows detachment site). **C**, SLAP III (two black arrows demonstrate the bucket handle split in the biceps attachment). **D**, SLAP IV. **E**, A lipstick biceps (white arrows mark edge of tendon), which represents inflammation of the LHB as it exits the glenohumeral joint.

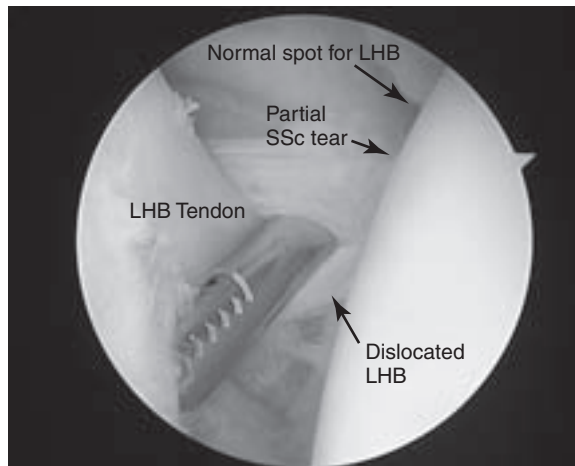


Figure 3-46 Arthroscopic image of a dislocated long head of the biceps (LHB) medially with a concomitant subscapularis tear (superior edge). The patient was treated with a LHB tenodesis (subpectoral) and debridement of the superior edge of the partially torn subscapularis tendon.

whereas in patients older than 40 there are usually preceding symptoms with a lower energy injury. It is imperative to rule out a subscapularis tear if an unstable biceps tendon is detected because these are often present together (Fig. 3-46) and vice versa.

SLAP lesions: As the diagnosis and management of SLAP lesions has progressed, three distinct mechanisms of injury have been proposed.

1. Traction injury
2. Direct compression
3. Overhead throwing or “peel back” lesion

In a traction injury an eccentric firing of the long head of the biceps muscle causes injury to the superior labrum complex. With a compression mechanism, there is a shearing force caused by the impaction of the superior glenoid rim. Synder et al. (1990) noted that this was most likely to occur during a fall onto an outstretched arm abducted and flexed slightly forward. Finally, Burkhart et al. (1998) proposed the existence of a biomechanical cascade in overhead athletes, resulting in a peel-back SLAP tear. Throwing athletes have increased shoulder external rotation and decreased internal rotation motion in the abducted position. These adaptations can be explained by lengthening of the anterior capsuloligamentous restraints and posterior capsular contracture and by increased proximal humeral retroversion in these athletes.

Biomechanical testing has validated each proposed mechanism. Bey et al. (1998) showed that biceps traction and inferior subluxation of the humeral head consistently created a SLAP lesion. Compression loading in cadaver shoulders has also shown that SLAP tears are more consistently created when the shoulder is forward flexed versus in an extended position. Last, the strength of the superior labrum biceps complex has been examined in multiple studies that simulate the phases of overhead throwing with a suggestion of increased stresses in late cocking and the conclusion that the position of the arm does influence the strain seen at the superior labrum.

Mechanism of Injury

Distal Biceps Tendon

Rupture of the distal biceps tendon is most likely to occur in the dominant extremity of men between the fourth and sixth decades of life. The average age at the time of rupture is approximately 50 years (range, 18 to 72 years). The mechanism of injury is usually a single traumatic event in which an unexpected extension force is applied to an arm flexed to 90 degrees and also supinated. Ruptures within the tendon and at the musculotendinous junction have been reported; however, most commonly the tendon will avulse from the radial tuberosity.

Treatment

Proximal Biceps

The initial treatment of proximal biceps pathology is nonoperative. Rest, avoidance of aggravating activities, ice, a course of anti-inflammatory medication, and formal physical rehabilitation will relieve the discomfort and increase function in most patients. Injections can also be a useful treatment and diagnostic tool and are typically used for patients with severe night pain or symptoms that fail to resolve after 6 to 8 weeks of conservative measures. The injection can be placed either in the glenohumeral joint or the biceps sheath. However, nonoperative treatment of biceps tendon instability is often unsuccessful in clinical practice. In some cases, this condition represents the natural progression of significant rotator cuff disease and the treatment must also focus on management of the rotator cuff tear.

Operative

There are no steadfast and discreet operative indications for proximal biceps pathology. However, typically surgery is considered after failure of nonsurgical treatment. An overhead throwing athlete should have undergone a period of rest followed by progressive rehabilitation. The surgical technique required to address the pathology is also not clear. It is important to consider the primary cause of the condition, location of the pathology, the integrity of the tendon, the extent of tendon involvement, related pathology, and patient activity level when planning the surgical intervention.

As stated previously, proximal biceps tendon pathology can be segmented into conditions involving degeneration/inflammation, instability, or SLAP lesions. Each subset has different treatment paradigms with corresponding surgical techniques. Degenerative or inflammatory conditions are often referred to as biceps “tendinitis” or “tenosynovitis” and require direct treatment of the diseased tendon. In contemporary shoulder surgery, the two primary options are a biceps tenotomy or tenodesis. Significant debate exists as to what the most appropriate method is and what exact technique provides the best outcomes.

Tenotomy consists of performing an intra-articular cut of the long head of the biceps tendon prior to its superior labral insertion. Tenodesis also requires a biceps tenotomy, but the long head of the biceps is then

securely anchored in its resting position with a variety of fixation techniques. Each procedure effectively relieves pain; however, the benefit of performing a tenodesis is that there is a maintenance of form and possibly function in the biceps. For example, Kelly et al. (2005) showed a 70% incidence of a “Popeye” deformity with tenotomy, which is higher than that reported in the literature. A “Popeye” deformity is a prominence in the biceps muscle resulting from retraction of the tendon (Fig. 3-44). However, Gill et al. (2001) reported the results of 30 patients treated with intra-articular tenotomy as the primary procedure for biceps degeneration, instability, and recalcitrant tendinopathy. Postoperatively, only two patients complained of activity-related pain that was moderate in nature, 90% returned to their previous level of sports, and 97% returned to their previous occupation.

A biceps tenodesis can be performed with either an open or arthroscopic surgical technique. The open technique consists of a subpectoral approach to the biceps tendon with either a suture anchor or interference screw used to secure the tendon to the proximal humerus. A variety of arthroscopic techniques have been described including suturing the tendon to the conjoint tendon, interference screw fixation, and suture anchor fixation. The significant difference between the open and arthroscopic techniques is that the arthroscopic technique does not address existent pathology in the bicipital groove because the biceps is anchored proximal to the groove. In the open procedure the long head of the biceps tendon is completely removed from the groove and secured distally. The decision between tenodesis and tenotomy is made on a patient-by-patient and surgeon-by-surgeon basis. Tenotomy offers a quick return to activities, whereas the young active patient concerned with cosmesis and supination strength will often prefer tenodesis.

A chronically subluxating or dislocating biceps tendon will also often show signs of advanced inflammation or degeneration. There is usually pathology traceable to the rotator interval and rotator cuff tearing, primarily involving the subscapularis. The indications for tenotomy or tenodesis parallel those discussed previously for significant biceps tendinopathy. Additionally, coexistent pathology must be addressed. In a patient with a subscapularis rupture and unstable biceps tendon, the subscapularis can be repaired with consideration given to a biceps tenotomy/tenodesis based on the condition of the tendon. An attempt at relocation of a subluxated or dislocated tendon may be possible if the tendon is still mobile and significant degeneration has not occurred. It is extremely important to repair and tighten the rotator cuff interval in this situation to maintain the position of the tendon in the groove. Recurrent instability, with a resulting stenosed, painful tendon, is a common long-term complication following any procedure that attempts to repair the sling and stabilize the tendon in the groove.

Debridement of the intra-articular portion of the biceps tendon has been suggested for partial tears, including delamination and fraying that involves less than 25% of the tendon in young, active patients or less

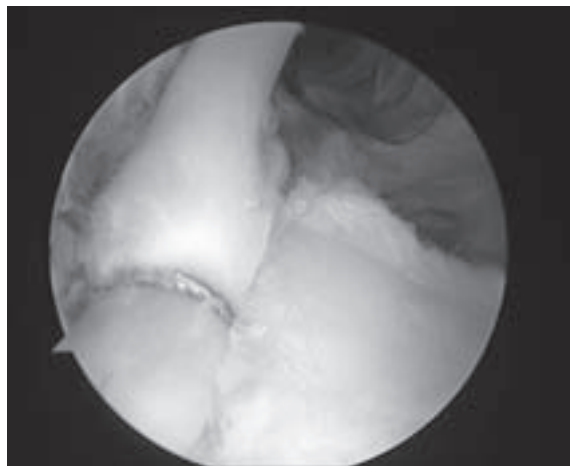


Figure 3-47 Arthroscopic image demonstrating final repair of a superior labrum anterior posterior (SLAP) 2 lesion; an anchor is used to repair the torn superior labral complex back to the superior glenoid.

than 50% of the tendon in older, sedentary patients. Often, this is accompanied by a decompression of subacromial soft tissue alone in younger patients or bursectomy and acromioplasty in older patients. Many authors believe that debridement alone is not effective in eliminating symptoms or preventing eventual biceps rupture; thus biceps tenotomy or tenodesis should be undertaken in these situations.

SLAP tears represent a significant source of shoulder pathology, and the available arthroscopic treatments are based on the type and classification of the pathology. Type I lesions can benefit from an arthroscopic debridement when there is substantial degeneration. Symptomatic type II lesions (Fig. 3-47) should be repaired by securing the superior labral complex to the glenoid with any of a variety of techniques; however, especially in less active patients, degenerative type II tears associated with other lesions typically do not require repair. Type III lesions are treated with resection of the unstable labral fragment and repair of the middle glenohumeral ligament if the ligament is attached to the torn fragment. Treatment of type IV tears depends on the extent of biceps tendon involvement and the age of the patient. A type IV SLAP tear includes a bucket handle portion of the labrum that extends into the biceps tendon. If the tendon is not too degenerative and the tear involves less than 30% to 40% of the tendon anchor, the tendon can simply be debrided and the superior labrum either debrided or reattached, provided the flap is large enough. If more than 40% of the tendon is involved, usually a side-to-side repair is performed, where possible, along with treatment of the labrum.

Distal Biceps

A trial of nonoperative treatment is advocated for patients with partial ruptures and elderly or sedentary patients with limited functional goals. Patients who opt for nonoperative treatment should be advised of a loss of 30% flexion strength and 40% supination strength and 86% decrease in supination endurance. Patients are

allowed early active-assisted range of motion initiated in the first week after injury. As motion returns to normal, progressive strengthening is advanced as tolerated.

Operative

Distal biceps rupture has become a more commonly recognized and treated entity, with an associated increase in the number of available repair techniques. The chosen repair technique reflects specific surgeon choice and the characteristics of the tear. With an acute tear, direct repair is often possible. However, a chronic tear can require soft tissue supplementation. Boyd and Anderson (1961) first reported a two-incision repair technique of an acutely injured tendon. This has been followed by several modifications and the development of a one-incision anterior technique. In the one-incision technique the injured tendon is identified and repaired to the radial tuberosity with a suture anchor, interference screw, or an endobutton. Techniques for chronic ruptures include descriptions of tendon grafting with autogenous semitendinosus, flexor carpi radialis, or allograft Achilles tendon. Furthermore, partial ruptures that do not respond to conservative treatment are also indicated for surgery with detachment and re-repair to the tuberosity. Each method has potential complications. There is a risk of heterotopic ossification development with the two-incision technique; however, many contemporary reports have stated that this can be avoided with meticulous dissection. The anterior approach has an increased risk of radial nerve injury. Regardless, either technique can successfully restore function in a ruptured or torn tendon with high patient satisfaction.

Rehabilitation Considerations

Proximal Biceps

Rehabilitation for Nonoperative Management Proximal Biceps/SLAP. Nonoperative treatment for proximal biceps pathology can be an effective treatment modality. However, it is necessary to correlate the reported physical impairments and the biceps pathology to ensure that therapy is addressing the correct underlying issue. Then, a treatment plan is developed to specifically focus on the impairments. Typically, the patient is advanced through different phases of rehabilitation, with individual modifications made based on the patient's pain, swelling, or motion.

- Phase I consists of pain management, restoration of full PROM, and restoration of normal accessory motion.
- Phase II consists of AROM exercises and early strengthening.
- Phase III entails rotator cuff and periscapular strength training, with a strong emphasis on enhancing dynamic stability.
- Finally, the return-to-sport phase focuses on power and higher speed exercises similar to sport-specific demands.

However, these phases and individual progression vary among patients. Patients who begin therapy with

full passive and active shoulder ROM are able to initiate resistance training on their first visit. Conversely, patients with an acute injury or onset of pain may need to be progressed more slowly. The therapist plays an instrumental role in developing a treatment plan in which the patient is progressed efficiently through the phases of rehabilitation with minimal irritation to the healing tissue.

Any rehabilitation program for a proximal biceps or SLAP injury should also focus on restoring strength to all muscles that provide dynamic stability to the shoulder. Rotator cuff strengthening has been recommended to improve shoulder function following biceps surgery. In addition to a rotator cuff strengthening program, rhythmic stabilization exercises can be used to retrain dynamic stability of the shoulder. Rhythmic stabilization exercises should be performed at varying shoulder and elbow positions because elbow position is thought to affect the function of the biceps at the shoulder.

Last, taking into account the injury mechanism, the therapist should avoid placing the arm in provocative positions. For example, if a compressive force caused the injury, patients should initially refrain from weight-bearing. This eliminates further compressive and shear forces on the labrum. An overhead athlete who is suspected of having a “peel back” lesion should not have the arm placed in excessive external rotation, and those with traction injuries should avoid initial heavy eccentric or resisted biceps contractions.

Rehabilitation for Biceps Tenodesis/Tenotomy

Management of biceps tenotomy differs compared to tenodesis. Because there is minimal tissue healing to occur, tenotomy rehabilitation follows the same prescription as that for a tenodesis but can be more aggressive and advance quickly. The primary risk of an aggressive approach is a “Popeye” deformity (Fig. 3-44), which occurs with retraction of the biceps tendon and muscle belly, producing a prominence in the anterior arm. However, this deformity is almost exclusively cosmetic and has not been shown to have an adverse functional consequence.

For a biceps tenodesis a discussion should be had between the surgeon and the therapist with regard to postoperative protocols. As stated earlier, there are numerous techniques for the tenodesis and each may have different rehabilitation requirements. For the biceps tenodesis procedure, the patient is initially instructed on modification strategies to protect the repair including avoidance of activities that cause contraction of the biceps muscle such as resisted elbow flexion and forearm supination. These motions are typically utilized during activities of daily living including lifting, opening door knobs, or using a screwdriver with the involved extremity.

In conjunction with activity modifications, rehabilitation after a biceps tenodesis will progress through a variety of phases based on the temporal relation to the surgical date. Rehabilitation Protocol 3-19 illustrates the protocol utilized by the senior author for rehabilitation after a subpectoral biceps tenodesis. In

parallel to these phases, successful biceps recovery requires the therapist to monitor and control associated pain, swelling, and irritation. Progressively loading a healing tissue can promote soft tissue healing as long as the applied load is appropriate to the patient's stage of healing. Sharma and Maffulli (2006) stated that tendon healing occurs in three broadly overlapping stages. Patients will progress through the stages at different rates. Treatment must be individualized, based on soft tissue healing and the patient's clinical presentation.

Rehabilitation for the Operative Management of SLAP Lesions

Three variables affect the postoperative rehabilitation from a SLAP repair:

1. Type of tear
2. Type of surgical procedure
3. Surgeon preference

In general, there is a period of immobilization followed by progressive ROM exercises and strengthening. The progress through these phases is governed by the patient's response and the procedure completed; a debridement can be more aggressively rehabilitated than a repair. As mentioned earlier, this rehabilitation must be completed in the context of the patient's complete pathology. For example, rehabilitation from a SLAP repair cannot be undertaken at the expense of significant rotator cuff disease.

Debridement is the most common surgical procedure to address symptomatic SLAP lesions. In this case, rehabilitation can be divided into four general phases. The goal of phase I is to attain limited pain-free PROM. In phase II, the patient is progressed to full AROM. Then, phase III consists of the initiation of weight training followed by phase IV and the return to full activity. Specific protocols are listed in Rehabilitation Protocol 3-20.

With a SLAP repair, patients are led through the same general steps of rehabilitation at a slower pace (Rehabilitation Protocol 3-21). The senior surgeon utilizes a five-phase protocol with phases I and II focused on PROM. Phases III and IV progress through the stages of active-assisted and full AROM, followed by a return to full activities in phase V. Specific protocols are listed in Rehabilitation Protocol 3-21. Overall, each surgeon

and injury may require individualized programs, and communication between the treating surgeon and therapist is essential.

Rehabilitation After Distal Biceps Repair

Similar to SLAP repairs, a variety of operative techniques and injury patterns significantly affect the postoperative rehabilitation for distal biceps repair. Again, there are three essential considerations for the rehabilitation program:

1. Type of injury (chronic, acute, or partial rupture)
2. Type of repair (e.g., endobutton, suture anchors, bone tunnels)
3. Surgeon preference

However, all patients will progress through similar stages with different time courses. With all repairs it is necessary to balance the protection of the biceps tendon for soft tissue healing with the need for elbow motion to prevent stiffness. Thus, a chronically ruptured tendon with an allograft supplemented repair may need a more gradual return to full extension than a partial tear that has been repaired with endobutton fixation. For example, Huber (2009) proposed the following protocol as published in *DeLee and Drez's Orthopaedic Sports Medicine* for a two-incision repair with bone tunnels:

- Initial: Splint at 90 degrees.
- Weeks 1–8: Active-assisted extension and passive flexion with a 10-degree increase in extension per week.
 - Hinged elbow brace with extension limits.
- Weeks 8–12: Discontinue splint with full ROM and progressive resistance training.
- Weeks 12–6 months: Strengthening.
- 6 months: Return to play for the athlete.

This protocol is more conservative than the procedure described by Greenberg et al. (2003). for a distal biceps tendon repair with a one-incision technique and endobutton fixation. The specifics for this program are listed in Rehabilitation Protocol 3-22, with strengthening beginning at week 6 and full return to play at week 12. These two protocols illustrate the importance of maintaining an open line of communication between the treating surgeon and the therapist.

ACROMIOCLAVICULAR JOINT INJURIES

Marisa Pontillo, PT, DPT, SCS

Anatomy

The acromioclavicular (AC) joint is a diarthrodial joint, which along with the sternoclavicular joint, connects the upper extremity to the axial skeleton. In adults, both articulating surfaces are covered by fibrocartilage. The AC joint is supported by the AC ligaments (i.e.,

superior, inferior, anterior, and posterior), which provide horizontal stability (Fig. 3-48), and the coracoclavicular (CC) ligaments (i.e., conoid and trapezoid), which provide vertical stability to the joint.

An articular disc (or meniscus) is present but commonly appears as an incomplete fibrocartilaginous ring,