

**TREATMENT OF CARTILAGE DEFECTS IN YOUNG SHOULDERS: FROM
THE LAB TO THE CLINIC**

**Geoffrey S. Van Thiel MD/MBA*, Andrew Riff MD, Wendell Heard MD, Vasili Karas BS,
Jas Chahal MD, Brian J. Cole MD/MBA**

Rush University Medical Center, Chicago, IL

***Rockford Orthopedic Associates, Rockford, IL**

Introduction

Glenohumeral cartilage defects in the young patient are a particularly challenging clinical problem given the longer life span of these patients and the greater demand that they place on their shoulders. Numerous etiologies can lead to glenohumeral cartilage disease (Table 1).^{1,2} The initial treatment is always non-surgical, but when conservative management fails there are a variety of surgical options available including palliative, reparative, restorative, and reconstructive techniques for cartilage defects in the shoulder.

At Rush, we are continually analyzing new bioconstructs and collagen matrices to augment cartilage procedures in the shoulder. The current study evaluates whether a collagen I/III matrix with microfracture can promote the formation of tissue with similar architecture to native cartilage by organizing adhesion, migration, and differentiation of mesenchymal stem cells to chondrocytes. The data suggests that both microfracture and Autologous Matrix-Induced Chondrogenesis (AMIC) have the ability to fill a glenohumeral cartilage defect in a rabbit model significantly more than the surgical control based on micro-CT data. Although the current study does not reveal significant differences, there are some very important conclusions that can be drawn. One, further research is needed to characterize the trends seen in this study. We currently have a pivotal animal study underway that will use histology and MRI to corroborate the results reported here. Two, the rabbit glenohumeral model is a very good *in vivo* model to study glenohumeral cartilage defects (Figure 1). Overall, this study provides a solid foundation for continued basic science research.

However, basic science research in isolation cannot address the issue of glenohumeral cartilage defects without clinical corollaries. At Rush, we continue to pioneer in the aforementioned areas of palliative, reparative, restorative, and reconstructive techniques for cartilage defects in the shoulder joint. In order to understand the potential applications of this basic science research, a framework is required to guide a clinical management algorithm.

Palliative Treatment

Palliative techniques for the management of glenohumeral cartilage disease are designed to alleviate symptoms without replacing or restoring the injured articular cartilage. These techniques consist primarily of arthroscopic debridement, capsular release, lavage, and loose body removal. Arthroscopic debridement is appealing because it is technically straightforward, has low surgical morbidity, and does not preclude other, more advanced, restorative and reconstructive interventions in the future.

In a few published series, arthroscopic debridement has led to good or excellent results in roughly 80% of patients at short follow-up intervals³⁻⁵. Cameron et al.⁶ reported on a series of patients with grade IV osteochondral defects and found that 88% experienced significant improvement in pain and function for an average duration of 28 months. Weinstein et al. also reported 80% good or excellent results at a mean follow-up of 34 months.⁵

The largest series in the literature is reported from Rush University Medical Center. Van Thiel, Romeo, Verma, and Cole et al⁴ retrospectively reviewed 81 patients who underwent arthroscopic debridement for glenohumeral osteoarthritis. Seventy-one patients were available for follow-up at an average of 27 months. Eighty-two percent of patients stated that they satisfied with the results of the surgery and would have it again. They also experienced a statistically significant improvement in postoperative functional outcome scores and a decreased level of pain. Sixteen patients (23%) were failures and underwent arthroplasty at a mean of 10.1 months after debridement. Grade IV bipolar disease, joint space less than 2 mm, and the presence of large osteophytes constituted the most significant risk factors for failure. Overall, arthroscopic debridement is a very reasonable first-line surgical option that offers predictable (70-80%) relief of pain and improvement in functionality.

Reparative Treatment

Reparative treatment includes marrow stimulation techniques like chondroplasty, subchondral drilling, and microfracture to replace the damaged cartilage with fibrocartilage (Figure 2). However, despite its reported effectiveness in the knee joint, we are aware of only three series that report clinical outcomes following microfracture in the shoulder joint.⁷⁻⁹ Siebold et al.⁹ and Millet et al.⁸ reported on small series of patients that underwent microfracture for full thickness chondral defects. At final follow-up there was a significant improvement in functional scores with an approximately 20% rate of revision procedures.

Our experience at Rush has been similar; Frank, Van Thiel, and Cole et al.⁷ reported minimum twelve months (mean, 28 months) follow-up on sixteen patients (seventeen shoulders) who underwent arthroscopic microfracture of the humeral head or glenoid surface. The 14 patients that were available for follow-up had statistically significant improvements in pain and function. Three patients (20%) went on to subsequent shoulder surgery and were considered to be failures. Additional research is needed before definitive statements can be made, but microfracture does appear to be a viable treatment option for select patient populations.

Restorative Treatment

Restorative treatments aim to reestablish hyaline or hyaline-like cartilage by transferring hyaline cartilage via osteochondral grafting (autograft or allograft) or growing hyaline-like cartilage using autologous chondrocyte implantation (ACI). At present, osteochondral autograft and ACI require a shoulder arthrotomy and a second surgical procedure at the knee for graft harvest. Consequently, both procedures are more invasive, more technically demanding, and expose the patient to significantly greater surgical morbidity than arthroscopic palliative or reparative techniques. Therefore, restorative modalities are best reserved for the young, active individual with a distinct chondral lesion of the humerus or glenoid who has already failed conservative, palliative, and reparative treatment.

Habermeyer et al.¹⁰ has published good results for seven patients that received osteochondral autograft transfer from the knee to the shoulder with almost nine year follow-up. The authors based their results on both functional as well as MRI criteria. Osteochondral allograft transfer employs a similar technique, matching a donor plug to a recipient site, but without the concern for donor-site morbidity. Therefore, allograft transfer can be used to treat more sizable lesions than can be treated effectively by autograft transfer. Given this versatility of osteochondral allografts, there are a number of case reports describing the use of side- and size-matched osteochondral allografts for large Hill Sach's lesions in the setting of recurrent instability.¹¹⁻¹³

At Rush, Cole and McCarty¹⁴ took this one step further and completed an osteochondral allograft humeral head resurfacing in combination with a lateral meniscal allograft glenoid resurfacing (Figure 3). In this case report, a 16-year-old girl with symptomatic bipolar glenohumeral chondrolysis after arthroscopic thermal capsulorrhaphy was treated with the meniscal and osteochondral allografts. At two year follow-up, the patient reported complete resolution of her shoulder pain, and radiographs showed maintenance of the glenohumeral joint space.

Romeo et al¹⁵ has also published a case report from Rush on the use of ACI in a 16-year-old baseball player with a humeral head lesion (Figure 4). Restoration was performed with a 2-stage harvest (knee) and implantation (shoulder) technique with harvest of a periosteal graft from the tibia. At 1 year, the patient had full range of motion without any pain. These case reports offer hope to young patients with end stage disease of the glenohumeral joint, but further research is needed to determine the long term outcome in a larger patient population.

Reconstructive Treatment

A number of reconstructive techniques, utilizing a combination of prosthetic and biologic coverage for the humeral head and glenoid have been developed. Specific techniques include soft-tissue interposition with fascia lata autograft, allograft Achilles tendon, allograft human skin (GraftJacket, Wright Medical Technology, Inc., Arlington, TN), or lateral meniscal allografts. Experience with these techniques is generally limited to a few institutions and literature reporting long-term outcomes is sparse.

Burkhead and Hutton proposed biological resurfacing of the glenoid with the interposition of soft tissue as a means of improving the outcome of hemiarthroplasty in young patients.¹⁶ They did report good results that were then supported by Huijsmans et al.¹⁷ with a similar technique involving the GraftJacket. Yamaguchi et al¹⁸ then proposed the use of a lateral meniscal allograft (LMA) as the interposition material (Figure 5 and Figure 6). The lateral meniscus is an attractive option given its favorable shape, load-bearing characteristics, and durability compared with other interposition materials.

However, at Rush University Medical Center extensive research has been carried out that questions these good results. Forty-five consecutive patients were treated with hemiarthroplasty

in conjunction with glenoid resurfacing with either LMA or GraftJacket. Short-term follow-up data (minimum 18 months) of 30-patients that underwent LMA resurfacing demonstrated promise as 94% of patients were satisfied with their clinical outcome¹⁹. However, at mean follow-up of 2.8 years, 21 of 41 patients (31 LMA, 10 GraftJacket) had experienced a clinical failure. Clinical failure was defined by conversion to TSA (8 cases), recommended conversion (5 cases), ASES score ≤ 5 (5 cases), disabling pain/loss of function (2 cases), or graft removal (1 case). These results illustrate the need for both appropriate patient selection and continued research.

Current Research Investigating Alternative Strategies for Glenoid Arthritis

No consensus exists in the literature regarding the most appropriate treatment option for glenohumeral chondral lesions in the young patient. The current report describes a multi-pronged approach using clinical and basic science studies to determine the best treatment options available to young patients with glenohumeral disease. Recent research in the knee has suggested that microfracture can be supplemented with various substrates in order to improve the results and characteristics of the cartilage defect repair. The purpose of this study is two-fold; to report the initial results of a novel technique to manage cartilage defects in the rabbit glenohumeral joint, and synthesize the clinical data from Rush regarding the management of glenohumeral lesions in young patients. It is hypothesized that a collagen I/III matrix superimposed on a chondral defect that has been concomitantly treated with microfracture will provide a medium on which functional cartilage will form and confer superior healing characteristics compared to tissue formed following microfracture only.

Methods

Twelve rabbits were divided into three groups. Group 1 consisted of rabbits that underwent removal of the cartilage layer on the glenohumeral joint only (surgical control). Group 2 rabbits then underwent microfracture to the glenohumeral defect (Figure 7). Group 3 had microfracture of the glenohumeral defect followed by the application of a collagen I/III matrix (AMIC procedure) (Figure 8). Each rabbit had one operative shoulder and one control non-operative shoulder. All operations were completed with the same exposure and closure.

The rabbits were then allowed to ambulate as tolerated. At 8 weeks post-op the glenohumeral joints of the rabbits were dissected and analyzed using a new micro-CT protocol to evaluate fill of the glenohumeral defect for each rabbit and every shoulder. ANOVA results and Tukey post-hoc testing was used to determine significant differences between the normalized values.

Results

The results for total cartilage volume and average cartilage thickness are displayed in Figure 9 and Figure 10. There are no significant differences in the statistical results, however there is a trend toward increased defect fill and thickness in the microfracture and AMIC groups. The

topographical surface maps for the surgical control and AMIC procedures are shown Figure 11. There were also no significant trends in the values for the attenuation values of the defect fill. However, a post-hoc power analysis showed that 10 specimen per group would be required to find statistical differences.

Discussion

Overall, a commitment to clinical and basic science research has provided a better understanding of both the etiology and best treatment patterns for management these young patients with the difficult problem of early shoulder degeneration. Future research will continue to yield new treatment modalities with the goal of increasing function and improving outcomes.

Tables

Table 1 - Etiologies for Glenohumeral Degeneration in the Young Patient

| | |
|-----------------------------|--|
| Trauma | Instability |
| Inflammatory Arthroplathies | Post-Infectious Degeneration |
| Foreign Body Reaction | Postarthroscopic Glenohumeral Chondrolysis |

Figures

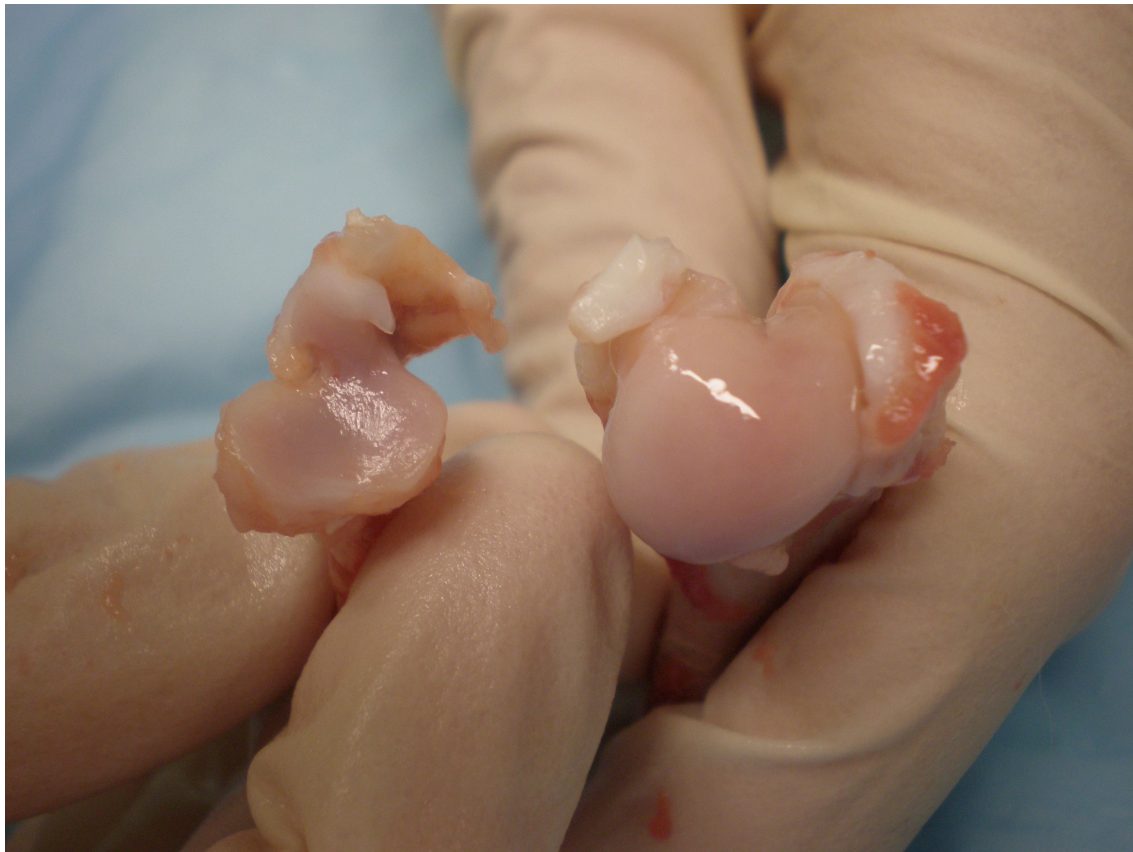

Figure 1 – Rabbit glenohumeral joint

Figure 2 - Microfracture of the glenoid in a young patient.

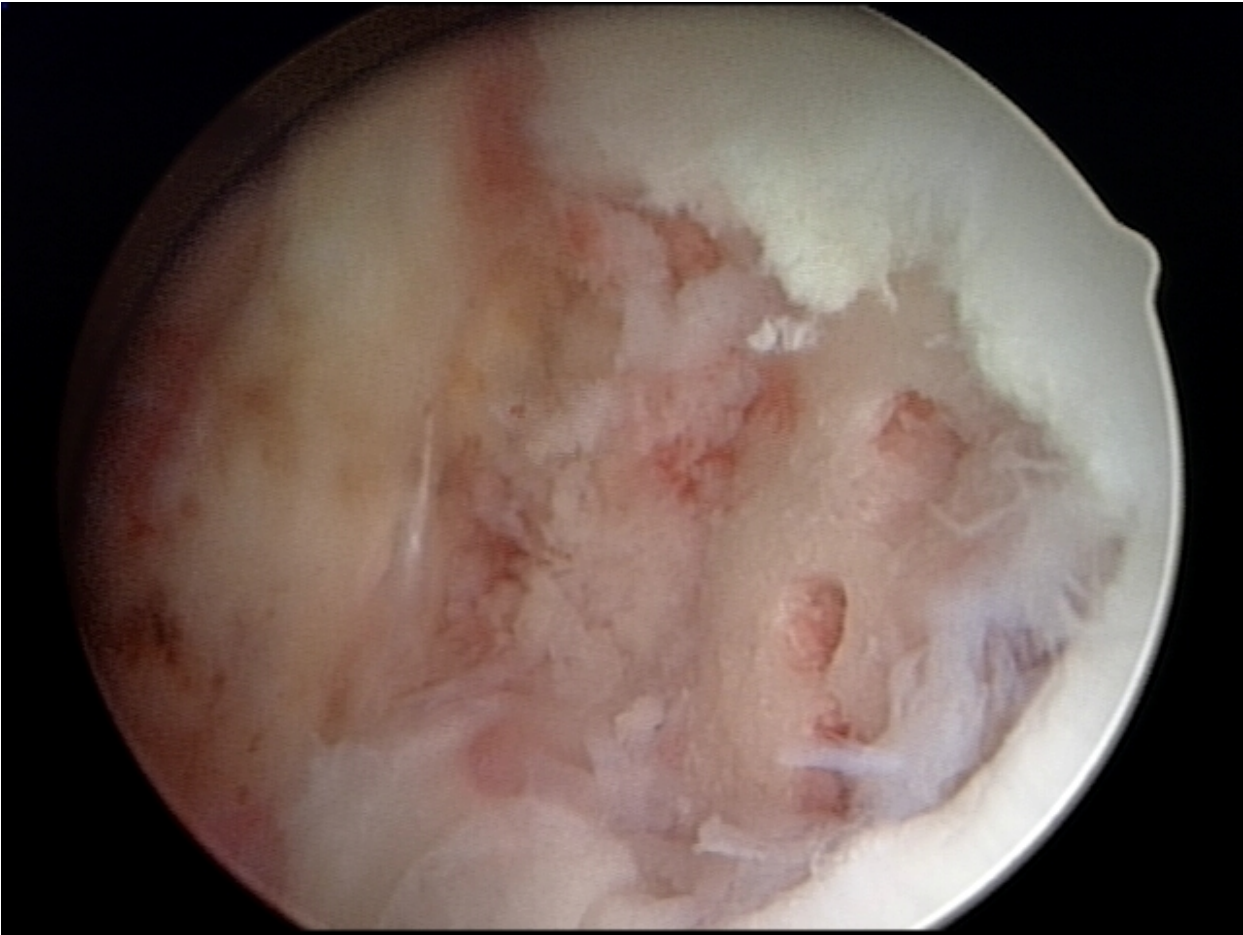


Figure 3 - Humeral Head Allograft in a Patient with Severe Degeneration of the Humeral Head

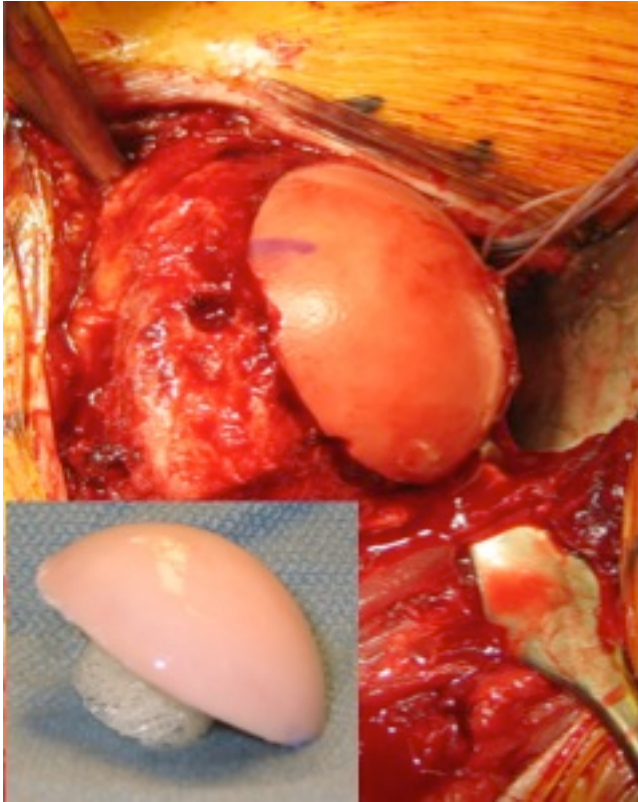


Figure 4 - ACI to the Humeral Head

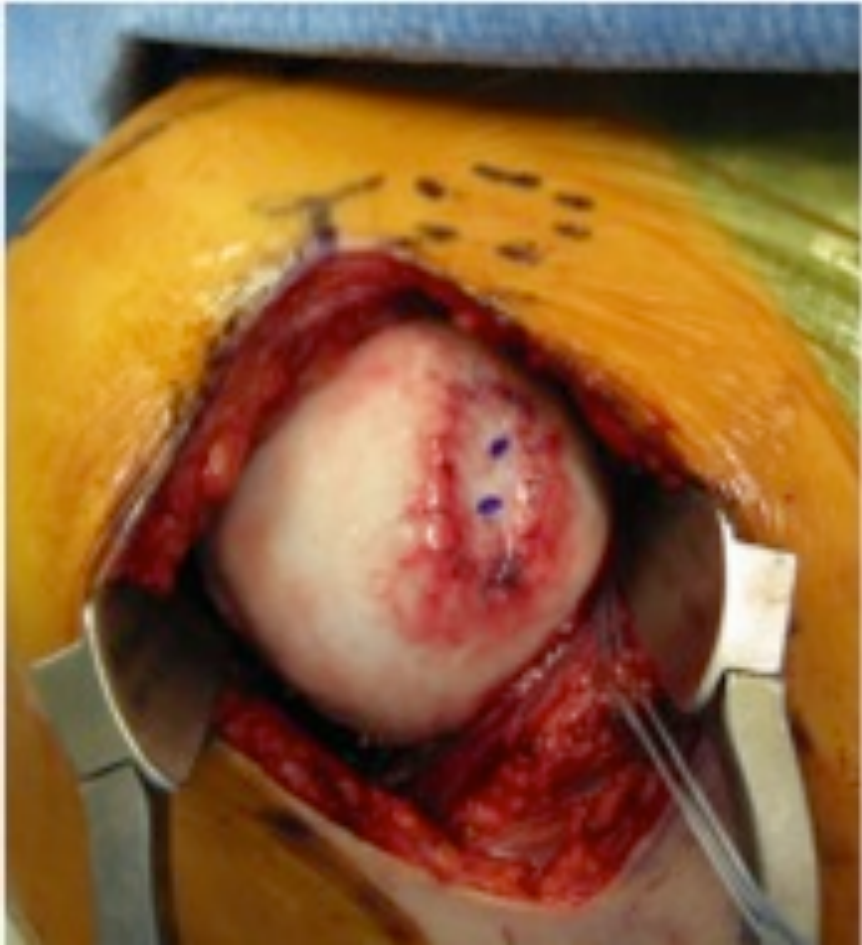

Figure 5 - Allograft Lateral Meniscus that will be Used to Resurface the Glenoid

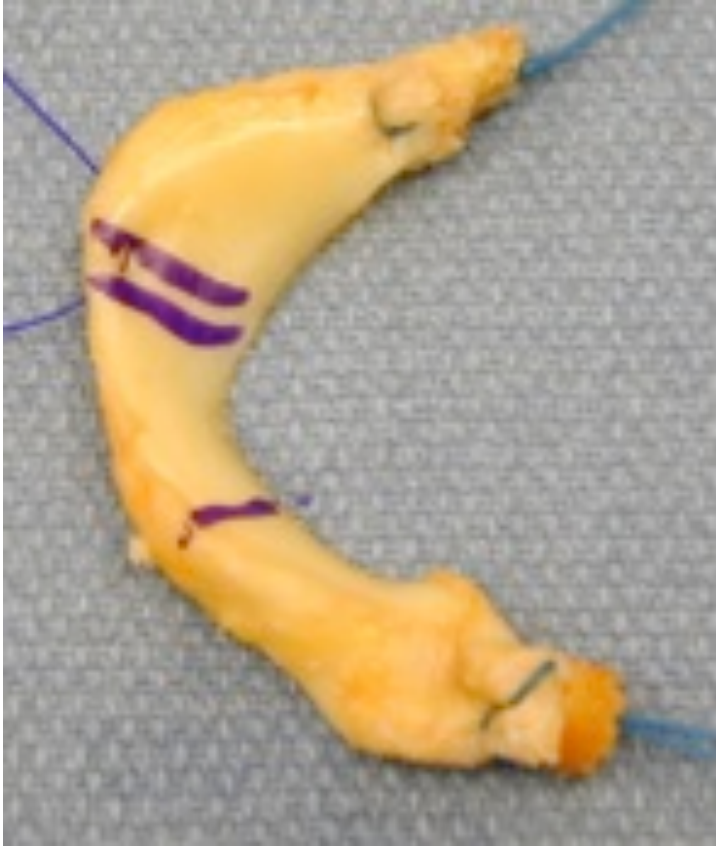


Figure 6 - Lateral Meniscus Sutured to the Glenoid

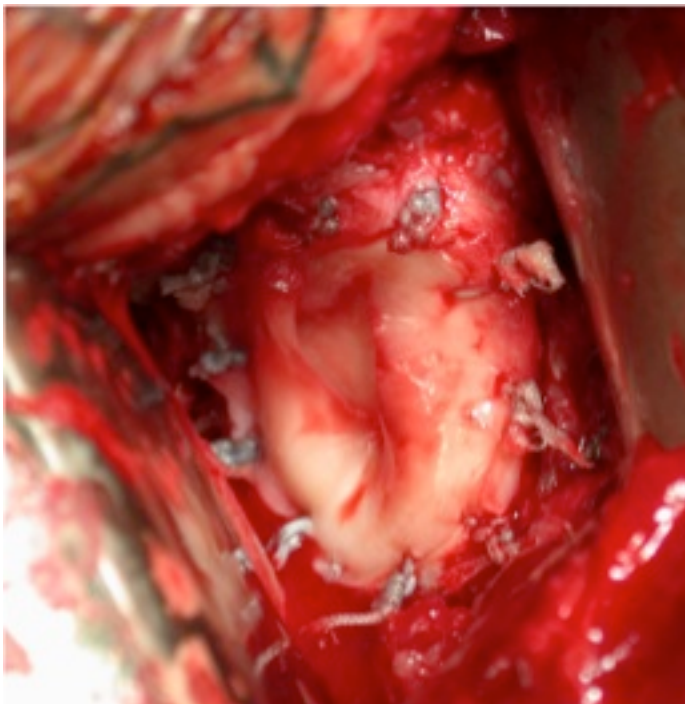
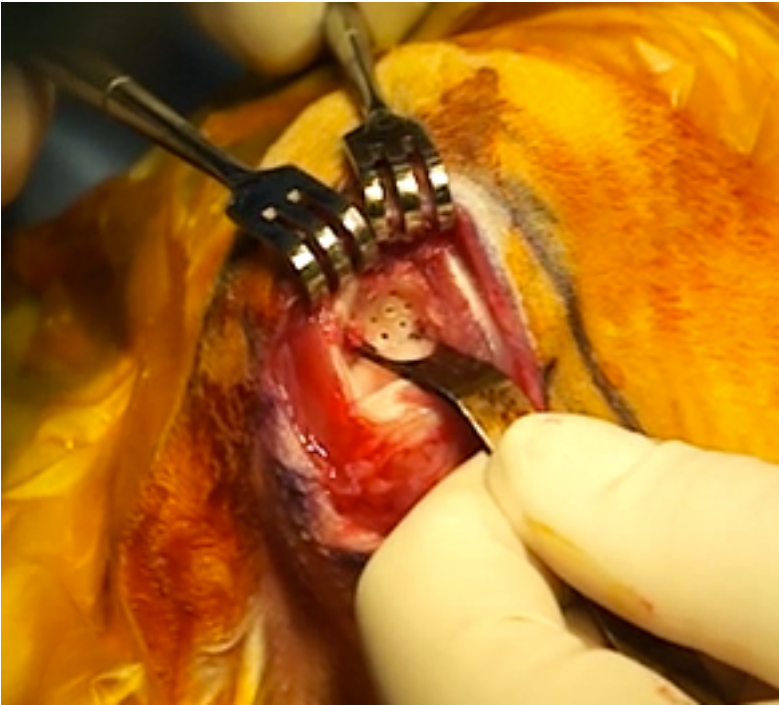

Figure 7 - Microfracture to a Rabbit Glenoid



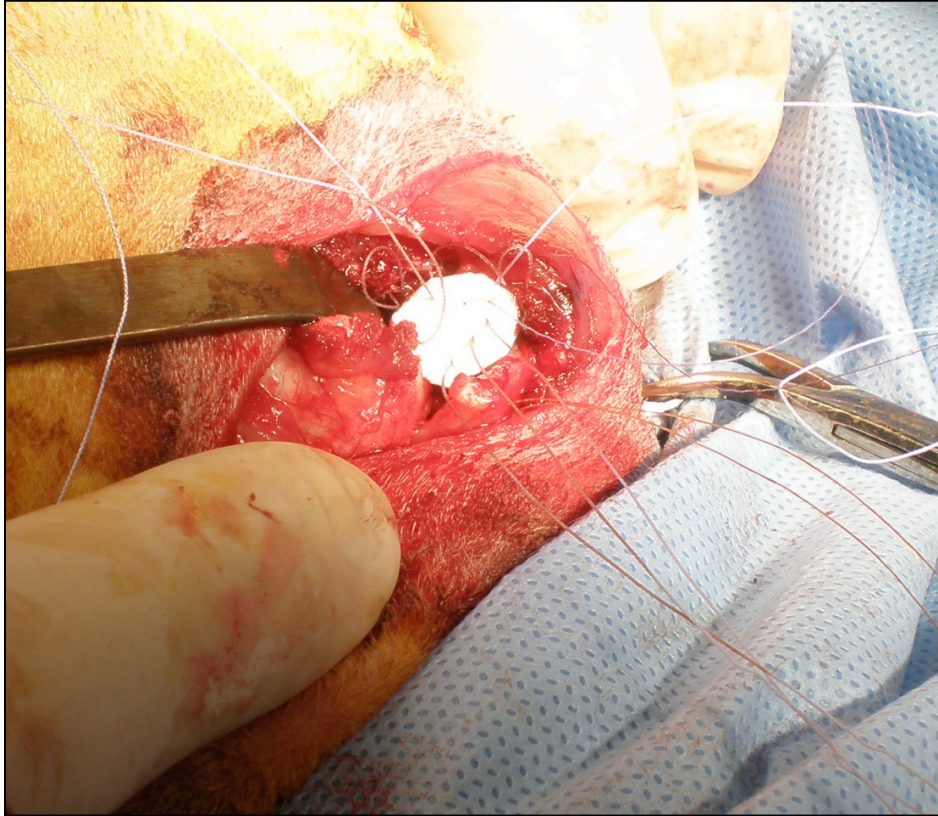


Figure 8 – Collagen I/III patch placed on the glenohumeral rabbit joint after microfracture.

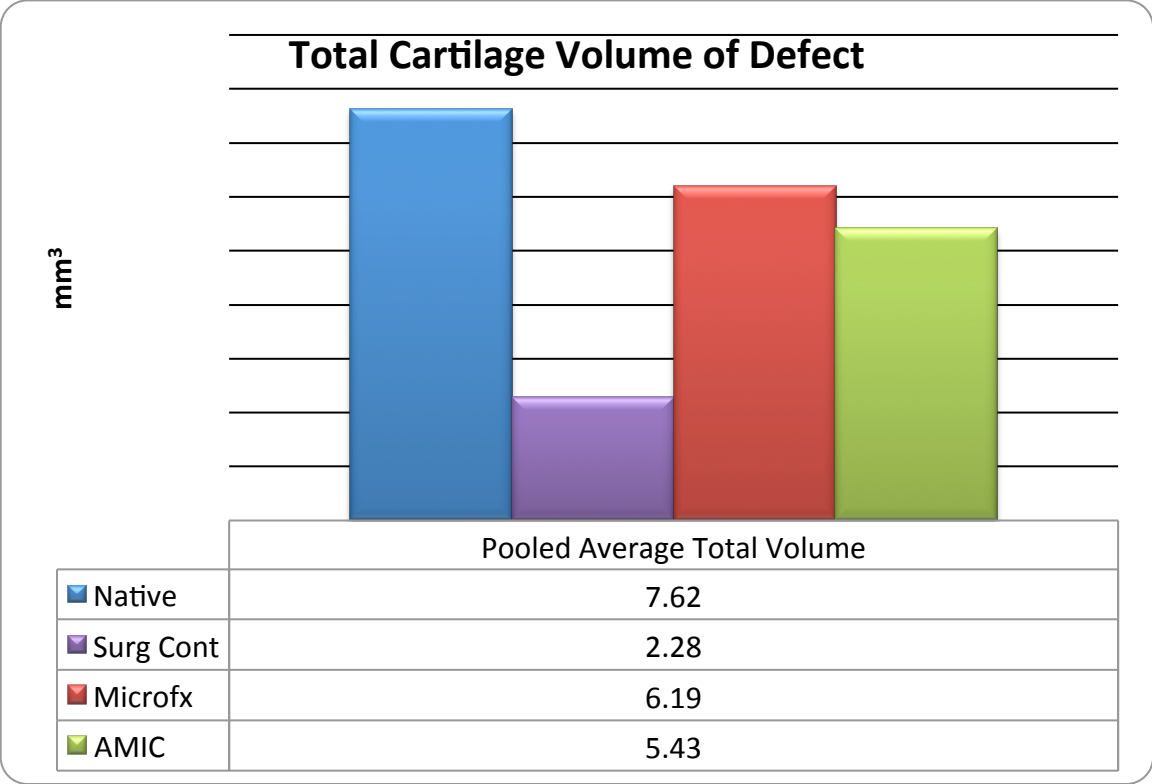


Figure 9 – Total cartilage volume of the glenohumeral defect in the rabbit joint.

References

1. Cole BJ, Yanke A, Provencher MT. Nonarthroplasty alternatives for the treatment of glenohumeral arthritis. *Journal of Shoulder and Elbow Surgery / American Shoulder and Elbow Surgeons ... [et Al.]*. 2007;16(5 Suppl):S231-240-S231-240.
2. McCarty LP, 3rd, Cole BJ. Nonarthroplasty treatment of glenohumeral cartilage lesions. *Arthroscopy: The Journal of Arthroscopic & Related Surgery: Official Publication of the Arthroscopy Association of North America and the International Arthroscopy Association*. 2005;21(9):1131-1142.
3. Safran MR, Baillargeon D. The role of arthroscopy in the treatment of glenohumeral arthritis. *Sports Medicine and Arthroscopy Review*. 2004;12(2):139-145.
4. Van Thiel GS, Sheehan S, Frank RM, et al. Retrospective analysis of arthroscopic management of glenohumeral degenerative disease. *Arthroscopy: The Journal of Arthroscopic & Related Surgery: Official Publication of the Arthroscopy Association of North America and the International Arthroscopy Association*. 2010;26(11):1451-1455.
5. Weinstein DM, Bucchieri JS, Pollock RG, Flatow EL, Bigliani LU. Arthroscopic debridement of the shoulder for osteoarthritis. *Arthroscopy: The Journal of Arthroscopic & Related Surgery: Official Publication of the Arthroscopy Association of North America and the International Arthroscopy Association*. 2000;16(5):471-476.
6. Cameron BD, Galatz LM, Ramsey ML, Williams GR, Iannotti JP. Non-prosthetic management of grade IV osteochondral lesions of the glenohumeral joint. *Journal of Shoulder and Elbow Surgery / American Shoulder and Elbow Surgeons ... [et Al.]*. 2002;11(1):25-32.
7. Frank RM, Van Thiel GS, Slabaugh MA, Romeo AA, Cole BJ, Verma NN. Clinical outcomes after microfracture of the glenohumeral joint. *The American Journal of Sports Medicine*. 2010;38(4):772-781.
8. Millett PJ, Huffard BH, Horan MP, Hawkins RJ, Steadman JR. Outcomes of full-thickness articular cartilage injuries of the shoulder treated with microfracture. *Arthroscopy: The Journal of Arthroscopic & Related Surgery: Official Publication of the Arthroscopy Association of North America and the International Arthroscopy Association*. 2009;25(8):856-863.
9. Siebold R, Lichtenberg S, Habermeyer P. Combination of microfracture and periosteal-flap for the treatment of focal full thickness articular cartilage lesions of the shoulder: a prospective study. *Knee Surgery, Sports Traumatology, Arthroscopy: Official Journal of the ESSKA*. 2003;11(3):183-189.
10. Scheibel M, Bartl C, Magosch P, Lichtenberg S, Habermeyer P. Osteochondral autologous transplantation for the treatment of full-thickness articular cartilage defects of the shoulder. *The Journal of Bone and Joint Surgery. British Volume*. 2004;86(7):991-997.

11. Gerber C, Lambert SM. Allograft reconstruction of segmental defects of the humeral head for the treatment of chronic locked posterior dislocation of the shoulder. *The Journal of Bone and Joint Surgery. American Volume*. 1996;78(3):376-382.
12. Giannini S, Buda R, Cavallo M, et al. Bipolar fresh osteochondral allograft for the treatment of glenohumeral post-traumatic arthritis. *Knee Surgery, Sports Traumatology, Arthroscopy: Official Journal of the ESSKA*. 2011.
13. Miniaci A, Gish W. Management of anterior glenohumeral instability associated with large Hill-Sachs defects. *Techniques in Shoulder and Elbow Surgery*. 2004;5:170-175.
14. McCarty LP, 3rd, Cole BJ. Reconstruction of the glenohumeral joint using a lateral meniscal allograft to the glenoid and osteoarticular humeral head allograft after bipolar chondrolysis. *Journal of Shoulder and Elbow Surgery / American Shoulder and Elbow Surgeons ... [et Al.]*. 2007;16(6):e20-24-e20-24.
15. Romeo AA, Cole BJ, Mazzocca AD, Fox JA, Freeman KB, Joy E. Autologous chondrocyte repair of an articular defect in the humeral head. *Arthroscopy: The Journal of Arthroscopic & Related Surgery: Official Publication of the Arthroscopy Association of North America and the International Arthroscopy Association*. 2002;18(8):925-929.
16. Burkhead WZ, Jr., Hutton KS. Biologic resurfacing of the glenoid with hemiarthroplasty of the shoulder. *Journal of Shoulder and Elbow Surgery / American Shoulder and Elbow Surgeons ... [et Al.]*. 1995;4(4):263-270.
17. Huijsmans P, Roberts C, van Rooyen K, du T DF, de Beer JF. The treatment of glenohumeral OA in the young and active patient with the Graft Jacket: preliminary results. *J Bone Joint Surg Br*. 2004;87:275-275.
18. Ball C, Galatz L, Yamaguchi K. Meniscal allograft interposition arthroplasty for the arthritic shoulder. Description of a new surgical technique. *Techniques in Shoulder and Elbow Surgery*. 2001;2:247-254.
19. Nicholson GP, Goldstein JL, Romeo AA, et al. Lateral meniscus allograft biologic glenoid arthroplasty in total shoulder arthroplasty for young shoulders with degenerative joint disease. *Journal of Shoulder and Elbow Surgery / American Shoulder and Elbow Surgeons ... [et Al.]*. 2007;16(5 Suppl):S261-266-S261-266.